

# **INTEGRATED SYSTEM**

---

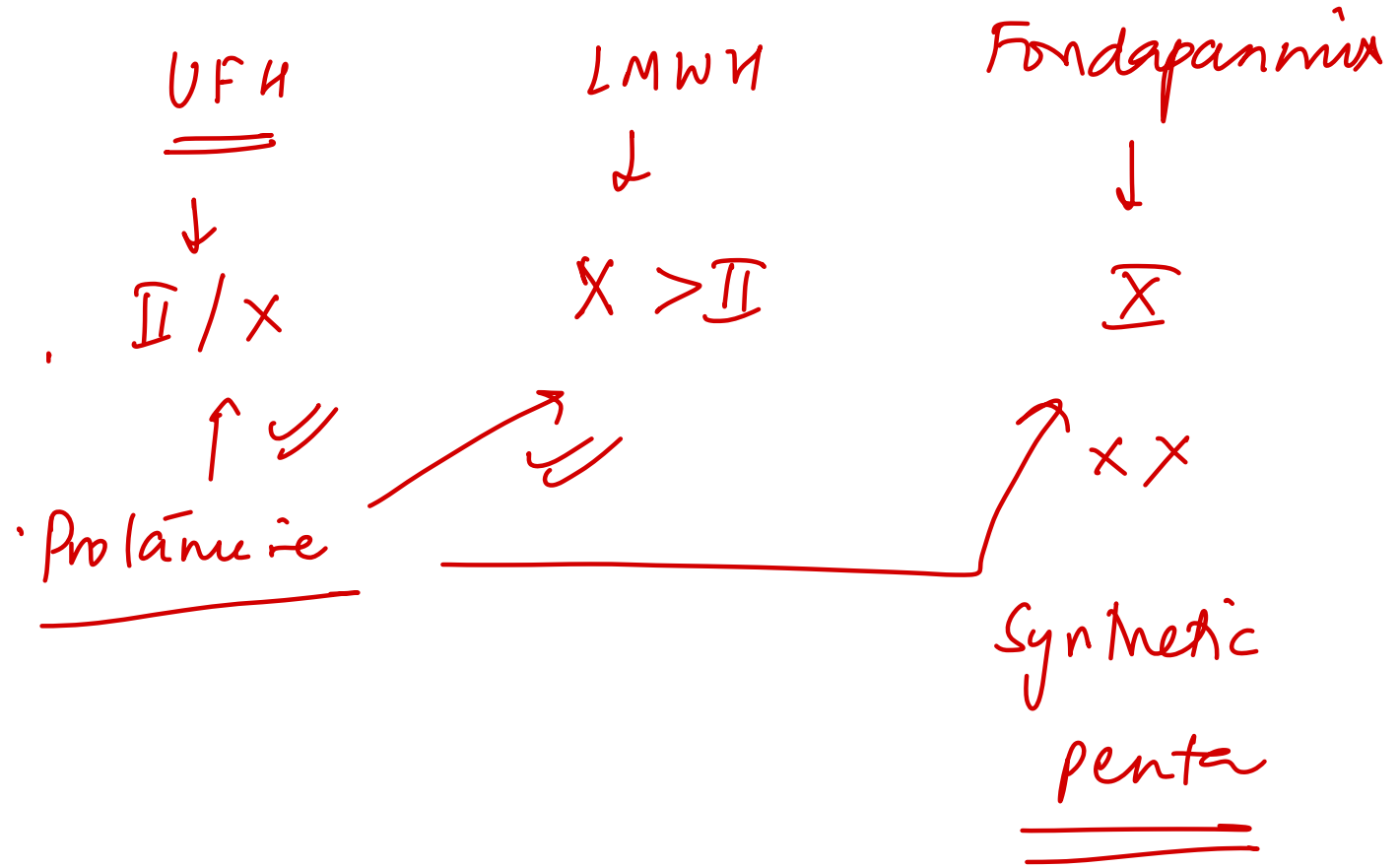
# **EXTRA-EDGE**

# **INTEGRATED HEMATOLOGY**

---

112. Which of the following anticoagulant agents will not respond to protamine sulfate?

- A. Unfractionated heparin
- B. Enoxaparin
- C. Dalteparin
- D. ~~Fondaparinux~~



113. All of the following anticoagulants inhibit both Factor Xa and Factor IIa, except:

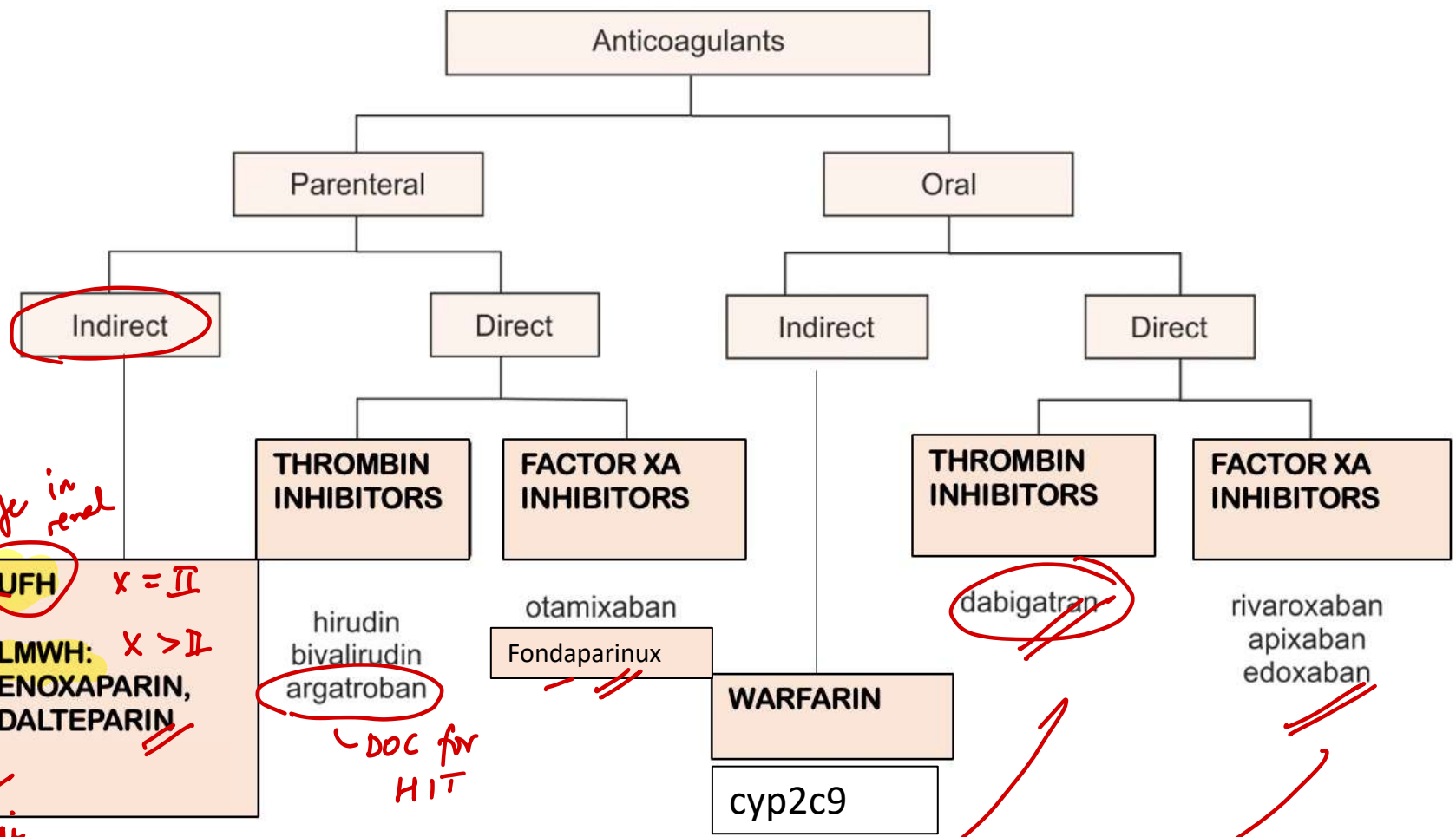
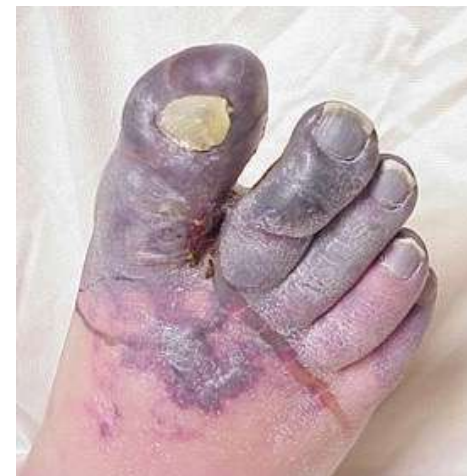A. Unfractionated heparin

B. LMWH

~~C. Fondaparinux~~ X

D. None of the above

# ANTICOAGULANTS-PHARMACOLOGY



*safe in renal*  
 ✓  
 HIT  
 ↓ platelet thrombocytosis  
 Pfa-anti

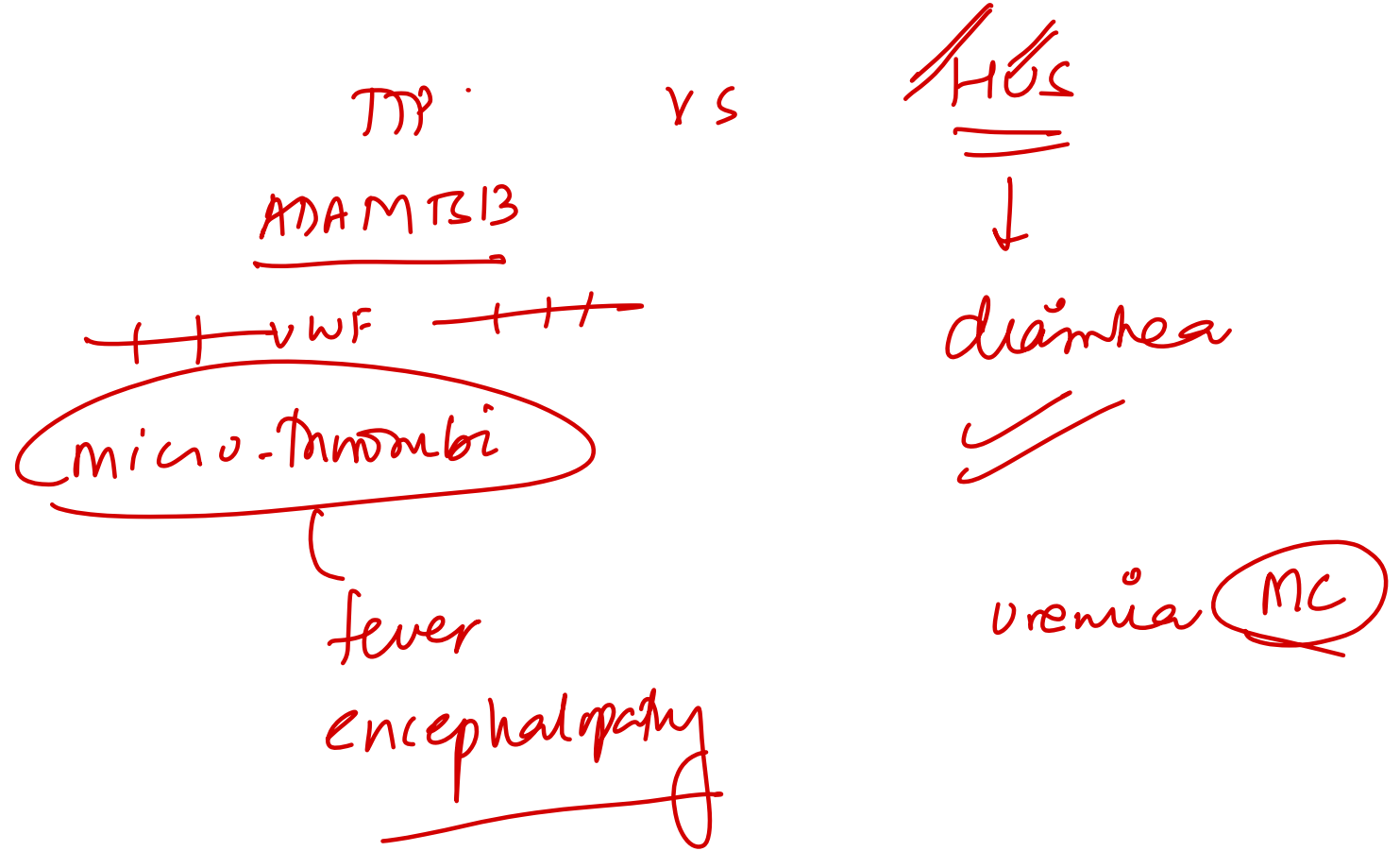
*DOC for HIT*

*PCC > FFP + vitK*

**Ciraparantag:** II + IXa ⊖

# 34. Which feature is not seen in thrombotic thrombocytopenic purpura (TTP)?

- A. Renal failure
- B. Hemolytic anemia ✓
- C. Altered sensorium ✓
- D. Deep Venous thrombus ✗



# 115. All are features of venous thrombus, except:

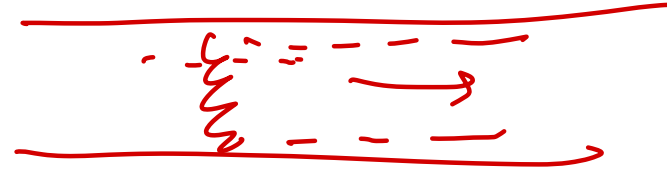
- A. Caused by turbulent ~~blood~~ flow *stasis*
- B. Common in deep leg veins
- C. Propagate in antegrade manner
- D. Composed mainly of red cells (red thrombi)

*arterial*

*retrograde*

*white*

*fibrin / p1t*



142. All of the following cause intravascular hemolysis, except:

- A. Mechanical trauma ✓
- B. Clostridial sepsis ✓
- ~~C. Hereditary spherocytosis~~
- D. ABO incompatibility

Hburia

MAHA

macroangiopathic - DIC / TTP / HUS

microangiopathic

Haptoglobin (↓) - Hemolysis

EVH  
 Splenomegaly  
 jaundice  
 gallstones  
AIHA

73. Which of the following is **not** associated with poor prognosis in a patient with multiple myeloma?

A. t(4;14)

B. High serum beta-2 microglobulin

C. Low serum albumin

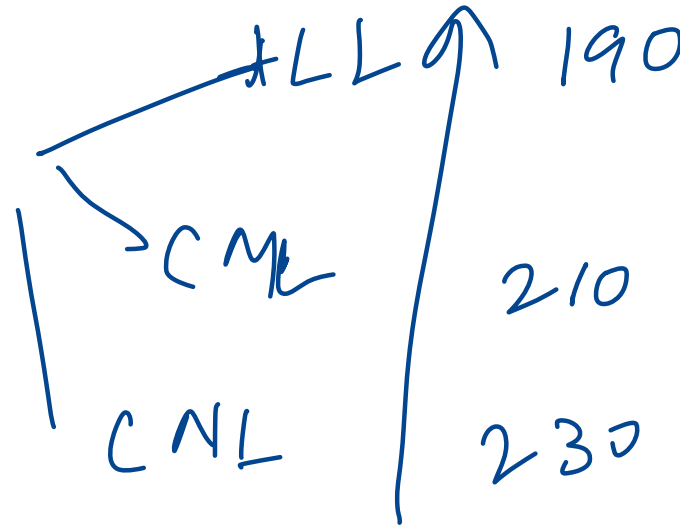
D. t(11;14)

Poor Prognosis	Good Prognosis
t(4;14), t(14;16), t(14;20), del(17p), aneuploidy, hypodiploidy	Hyperdiploid,
↑ beta-2 macroglobulin	t(11;14)
Plasmablastic morphology	t(6;14)
Low serum albumin	cyclin D1/D3+

$$\underline{\underline{6 + 4 = 11}}$$

63. Patients with all of the following are classified as AML with recurrent cytogenetic abnormalities except:

- A. Inversion 16 ✓
- B. PML; RARRA translocation ✓
- C. CEBPA mutation ✓
- D. t(9;22) Ph chromosome

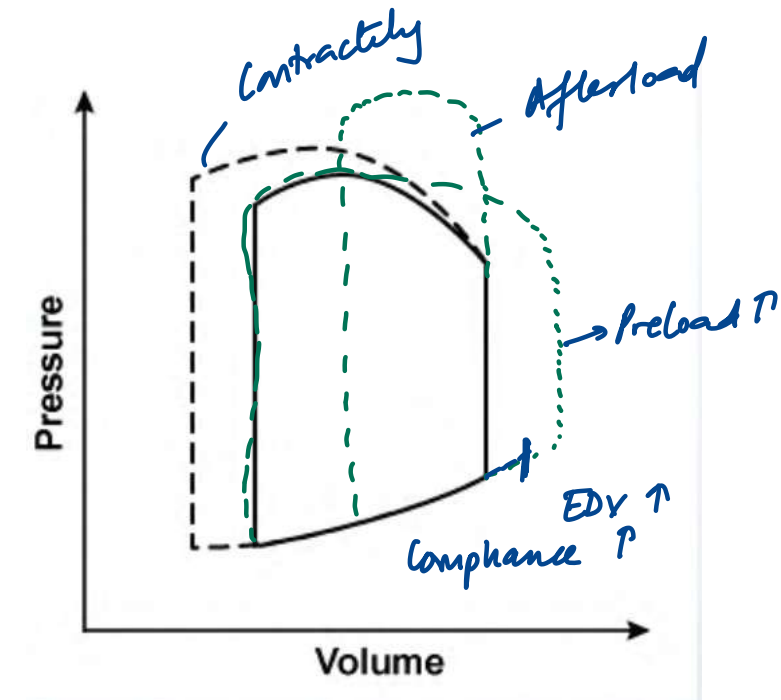


# INTEGRATED CVS

---

3. A 54-year-old man is admitted to the hospital due to cough, shortness of breath, and chest discomfort. He has a known history of coronary artery disease and underwent coronary artery bypass graft surgery 3 years ago. As a result of drug therapy, the left ventricular pressure-volume loop changes from a solid to a dashed line, as shown below. Which of the following parameters is most likely increased as a result of this change?

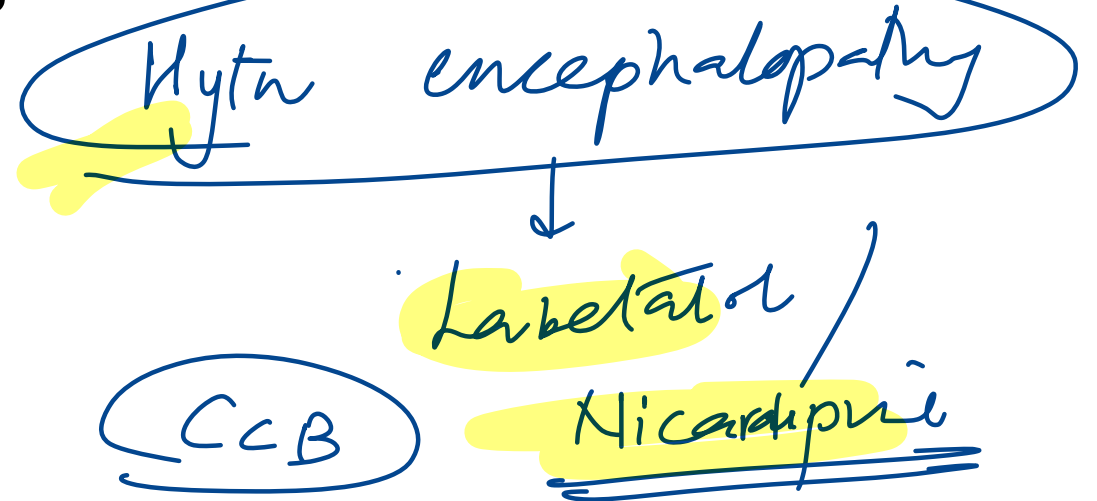
- A. End-diastolic pressure ~~XX~~
- B. End-systolic volume  $\downarrow$  ~~ESV~~
- C. Stroke volume
- D. Ventricular compliance ~~XX~~



10. A 56 year old asthmatic patient presents with severe headache and vomiting. BP is 220/130 mmHg, and fundus shows papilledema. What is the mechanism of action of the drug of choice?

- A. Stimulation of guanylyl cyclase
- B. Calcium channel blockade
- C. K<sup>+</sup> channel opening
- D. Increased cAMP

NO ↑



♥ → Nitroglycerin / Nitrates

BAÑO

11. A 32-year-old woman, a former elite swimmer, presents for a preconception checkup. She feels well and reports no symptoms. Vital signs are normal. Compared to a sedentary individual of the same age and sex, which cardiac changes are most likely?

Endurance

- A. Decreased ejection fraction, increased cavity size, increased cardiac output
- B. Increased ejection fraction, decreased cavity size, increased cardiac output
- C. Increased ejection fraction, decreased cavity size, unchanged cardiac output
- D. Unchanged ejection fraction, increased cavity size, increased cardiac output
- E. Decreased ejection fraction, unchanged cavity size, unchanged cardiac output

Condition	LV Mass	LV Cavity Size	LV Ejection Fraction	LV Diastolic Function
Dilated Cardiomyopathy	Increased	Increased	Decreased <i>systolic</i>	Normal
Hypertrophic Cardiomyopathy	Increased	Decreased	Preserved ✓	Impaired
Restrictive Cardiomyopathy	Normal	Normal	Preserved ✓	Impaired
Athlete's Heart	Increased	Normal or Increased	Preserved ✓	Normal

### Athlete's Heart – Cardiac Adaptation to Endurance Training

• **Increased stroke volume** → ↑ cardiac output (up to 35–40 L/min)

• Due to **eccentric hypertrophy**:

- ↑ LV cavity size
- ↑ diastolic filling capacity

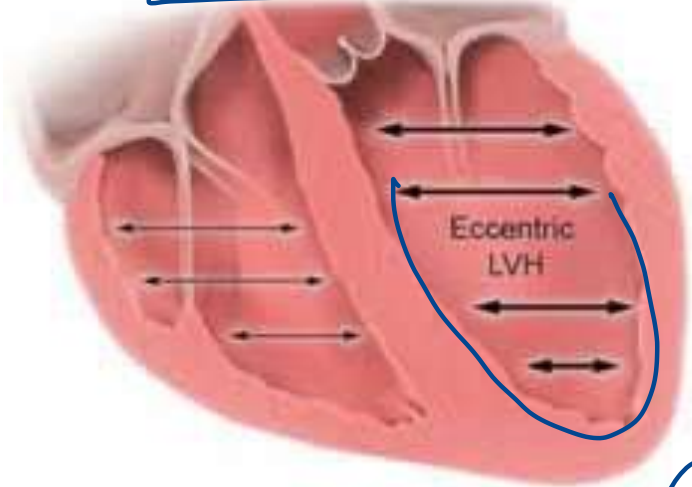
• Associated with:

- ↑ blood volume
- ↓ systemic vascular resistance (SVR)
- ↑ preload

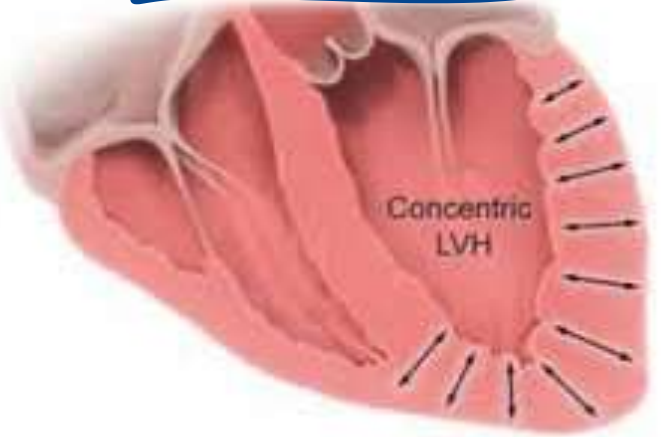• **LV ejection fraction** remains **mostly unchanged**

• **Educational Objective:** Endurance training causes proportional increase in end-diastolic volume and stroke volume without altering ejection fraction.

**Endurance training**



**Strength training**



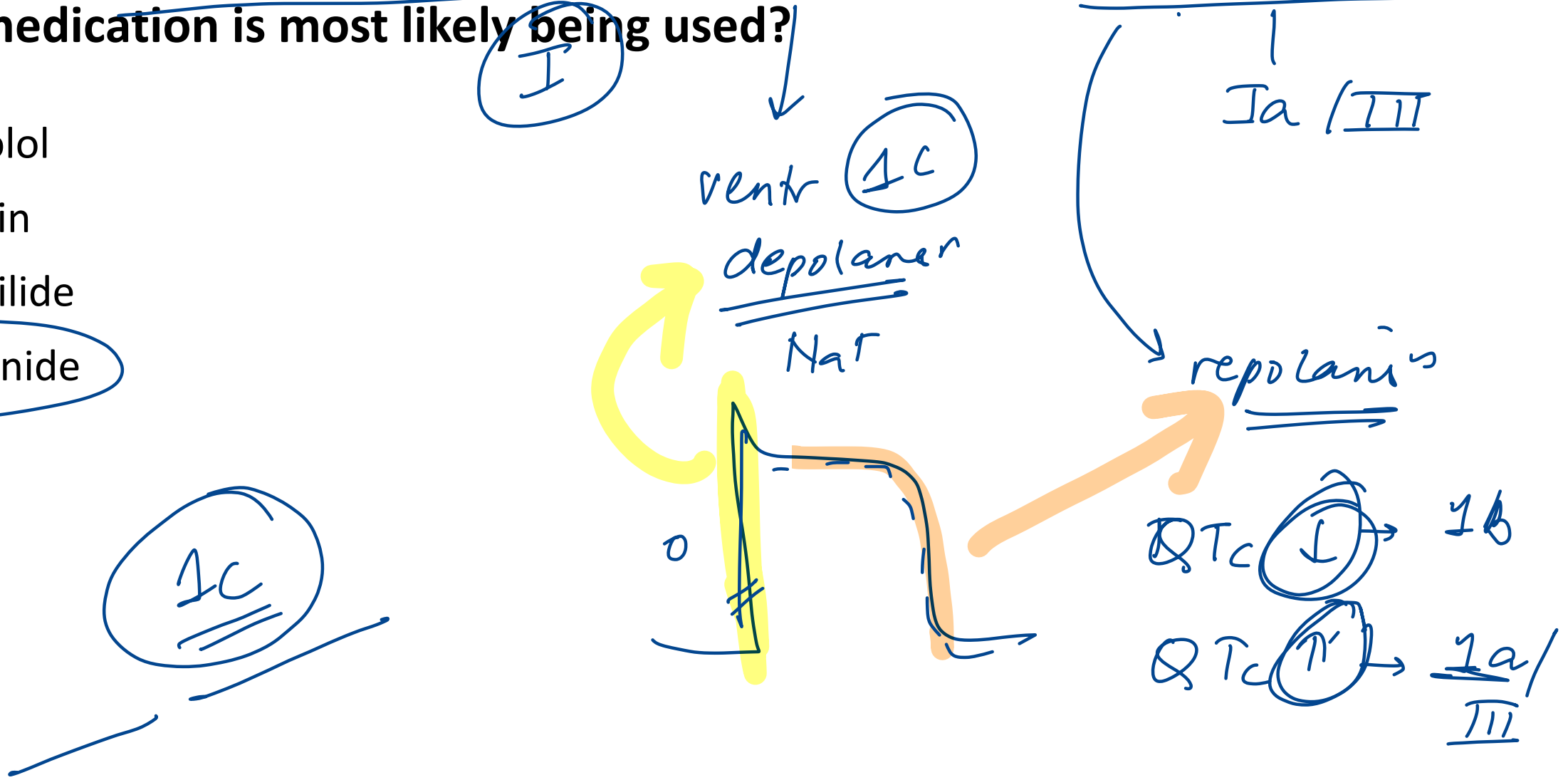
- Increased LV cavity size (ie, eccentric hypertrophy)
- Increased RV cavity size
- Increased diastolic filling and stroke volume
- Unchanged LV ejection fraction

EF (N)

- Increased LV wall thickness (ie, concentric hypertrophy)
- No RV changes
- Unchanged diastolic filling
- LV ejection fraction unchanged or slightly increased

20. A 45-year-old man with paroxysmal atrial fibrillation undergoes exercise ECG. His QRS increases from 95 msec to 125 msec; QTc remains normal. Which medication is most likely being used?

- A. Atenolol
- B. Digoxin
- C. Dofetilide
- D. Flecainide



# Antiarrhythmic drugs

I (Avoid with HyperK)

IA: **K-**: Quinidine, Procainamide, Disopyramide :

IB: **K +**: Lignocaine, Phenytoin

IC: **K no**: Fleicanide, Propafenone

II

III-**Amiodarone**, Ibutilide, Dofetilide, Sotalol (Avoid with HypoK)

IV



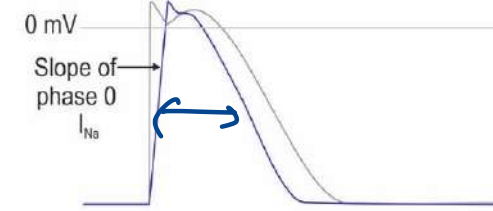
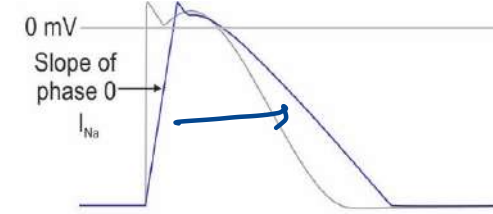
V: Adenosine

Dose:

Theophylline/ Caffeine:

	<u>QT</u>	QRS
IA	↑	↑
IB	↓	↑
IC	<b>N</b>	↑

	QT	QRS
III	↑	<b>N</b>



Cell action potential

Amiodarone:

PIs

Check

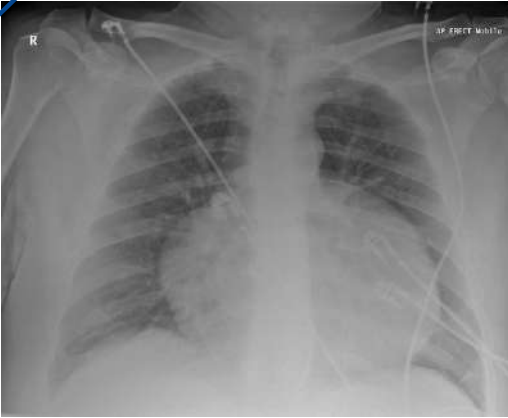
PFT

LFT

TFT

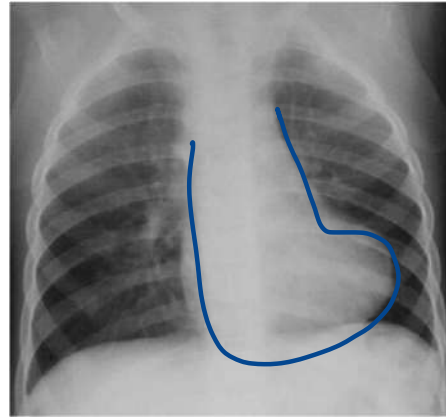
27. A 28-year-old man presents with chest tightness and dyspnea. ECG shows sinus tachycardia and low voltage QRS complexes with beat-to-beat variability. What is the most likely chest x-ray finding?

A.



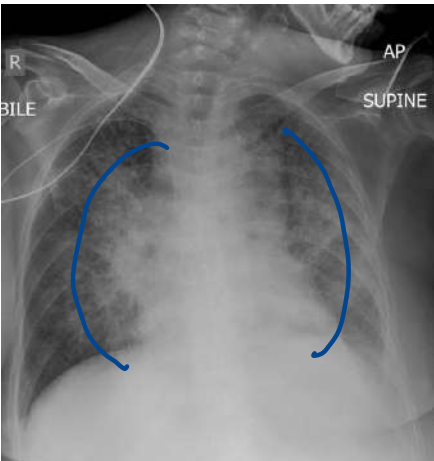
maney bag

B.



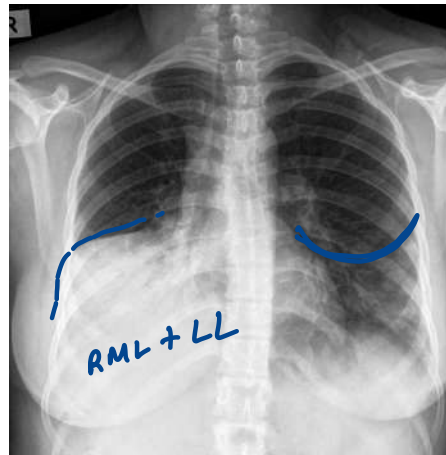
TOE

C.




batwing

D.



RML + LL

pericarditis  
pericardial  
effusion  
tamponade



55. A 52-year-old man comes to the OPD due to periodic substernal chest heaviness. The pain is precipitated by fast walking and remits after 5 minutes of rest. He has a history of hypertension and smokes. BP is 140/80 mm Hg, pulse 80/min. No murmurs or edema.

Which of the following pathologic states is most likely to be present in this patient?

Stable angina

- A. Atherosclerotic plaque obstructing ~~50%~~ of the coronary artery lumen, no thrombus
- B. Atherosclerotic plaque obstructing 80% of the coronary artery lumen, no thrombus
- C. Significant coronary artery vasospasm causing flow obstruction *Prinzmetal*
- D. Ulcerated atherosclerotic plaque with partially obstructive thrombus

Critical narrowing > 70%



fully )  
STEMI / NSTEMI



**79. Which of the following changes in the heart will not be suggestive of normal aging?**

A. Increased left atrial cavity size ↗

B. Fibrous thickening of valves

C. Increased left ventricular cavity size

D. Elastic fragmentation of aorta



94. A 68-year-old man comes to the OPD due to several weeks of progressive exertional dyspnea and lower extremity edema. Echocardiography shows biventricular dilation and a left ventricular ejection fraction of 35%. After initial stabilization, long-term use of which of the following medications will most likely improve survival in this patient?

- A. Amiodarone
- B. Amlodipine
- C. Carvedilol
- D. Digoxin

ACE ⊖ / ARB

B M C  
ARNI  
SGLT2 ⊖  
MRA

# 184. Which part of the vascular system has the greatest compliance?

A. Capillaries

B. Aorta

C. Arteries

D. Veins

$a_1 v_1 = a_2 v_2$  max area / min vel

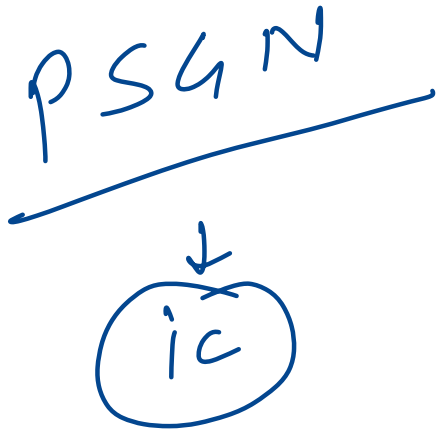
Windkessel effect

arteriole → max TPR

Capacitance

25. A 7-year-old boy is brought to the clinic after passing red-colored urine. He had a recent skin infection treated with antibiotics. On exam, he has periorbital and pedal edema. Labs reveal: BUN 14 mg/dL, Creatinine 1.4 mg/dL. Which of the following mechanisms most likely underlies his renal condition?

- A. CD8+ T lymphocytes -IV
- B. IgG immune complexes
- C. Histamine release -I
- D. IgG autoantibodies -II



60. A 68-year-old woman presents with recurrent syncope. She takes lisinopril, amlodipine, and clonidine. After stopping a medication, the syncopal episodes resolve. Which of the following mechanisms most likely explains the drug's effect?

- A. Decreasing presynaptic release of acetylcholine
- B. Decreasing presynaptic release of norepinephrine
- C. Blockade of beta-1 receptors in the sinoatrial node
- D. Blockade of calcium channels in the atrioventricular node

$\alpha 2$  (+)

Rebound hypertension

L-shaped curve

199. Which of the following statements are true of the baroreceptor reflex pathway?

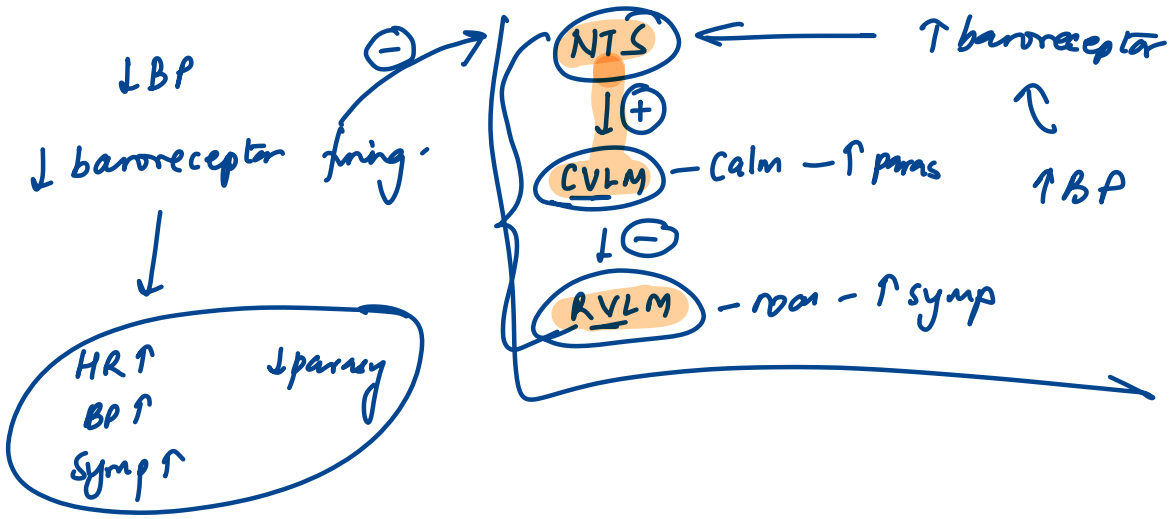
1. Rostral ventrolateral medulla (RVLM) is inhibited by CVLM. (T)
2. Caudal ventrolateral medulla (CVLM) releases GABA. (T)
3. Nucleus tractus solitarius (NTS) releases ~~GABA~~. *Glutamate* (T)
4. Stretch receptors are stimulated by increased blood pressure (T)

A. 1, 2, 3, 4

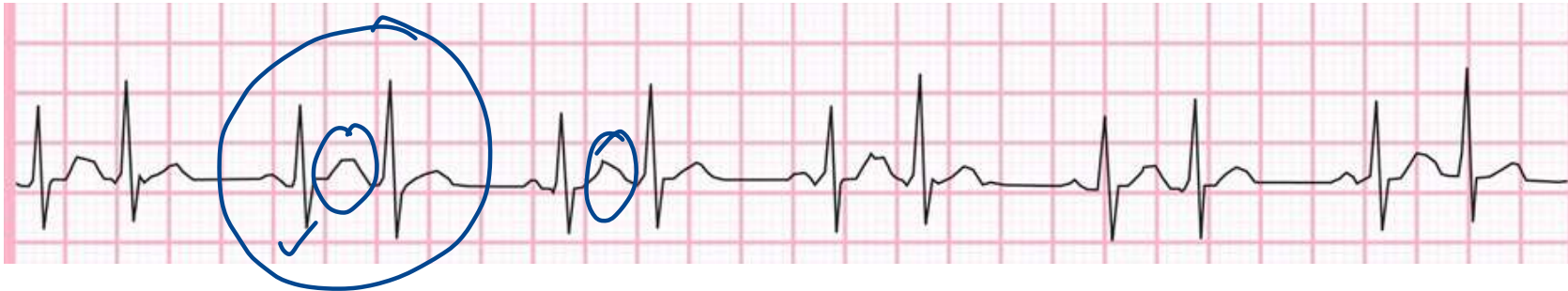B. 1, 2, 4

C. 3, 4

D. 1, 2

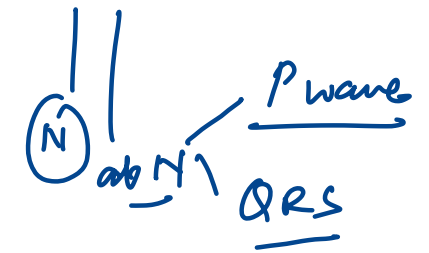


128. A 17-year-old boy presents with sudden-onset palpitations and lightheadedness while playing video games. He states this has occurred intermittently over the past year, but the episodes typically resolve spontaneously after a few minutes. He denies chest pain, shortness of breath, or syncope. ECG is shown below. Which of the following abnormalities is most likely present in this patient?



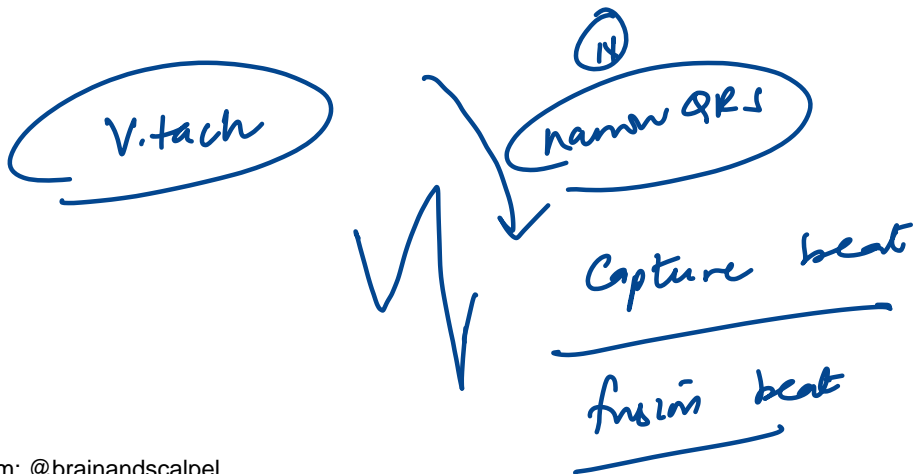
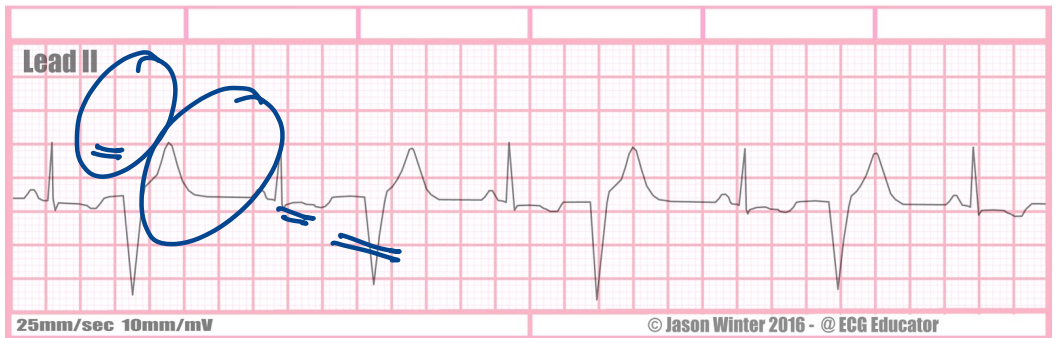
atrial bigeminy

ventricular



- A. Accessory pathway bypassing the AV node
- B. Degeneration of the atrioventricular conduction system
- C. Ectopic atrial pacemaker activity
- D. Dysfunction of the sinoatrial node

# Ventricular Bigeminy

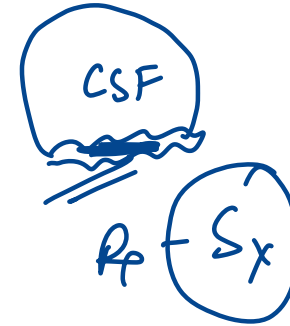
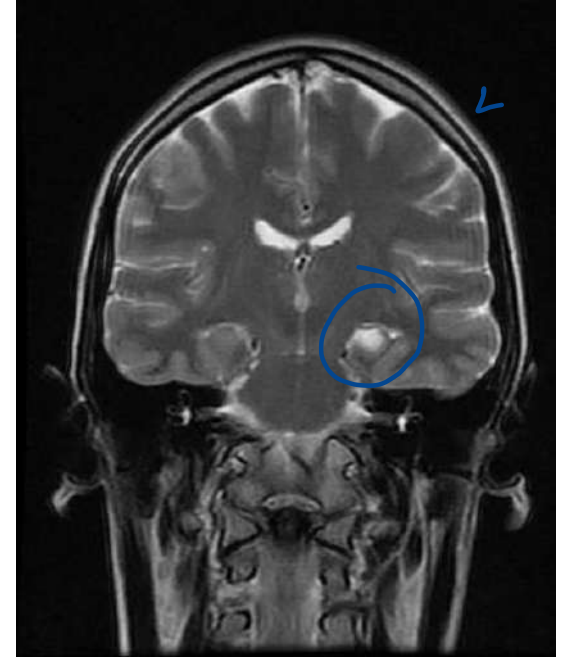


# INTEGRATED NEUROLOGY

---

19. A 10-year-old boy develops jerky movements and chewing motion, followed by unresponsiveness. MRI is shown below. Most likely diagnosis?

- A. Juvenile myoclonic ~~epilepsy~~
- B. Gelastic epilepsy
- C. Mesial temporal lobe epilepsy
- D. Lennox-Gastaut syndrome



IOC - MRI

Refractory epilepsy

F/U (+)

44. A motorcyclist suffered a head injury 6 months back and presents with persistent memory deficits following injury. Choose the most appropriately matched option related to memory?

- A. Hippocampus and implicit memory ✗
- B. Neocortex and associative learning ✗
- C. Medial temporal lobe- Declarative memory
- D. Angular gyrus- procedural memory ✗

## Declarative / Explicit Memory:

### • Semantic (factual):

- Prefrontal cortex <sup>2/1</sup>
- Temporal cortex (lateral and anterior)

### • Episodic (events):

- Hippocampus
- Medial temporal lobe
- Neocortex

## Nondeclarative / Implicit Memory:

### • Procedural (skills, habits):

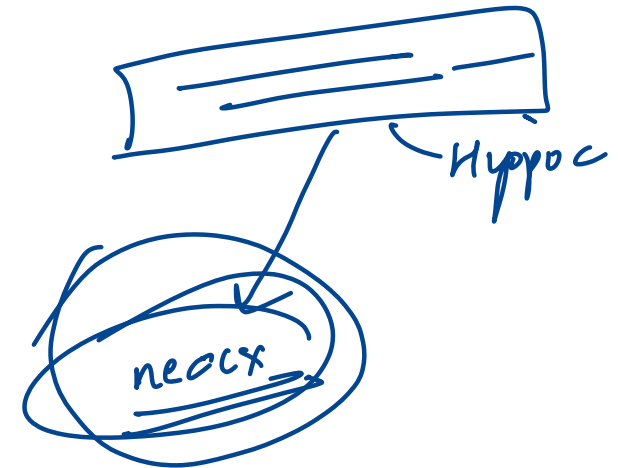
- Striatum
- Cerebellum
- Motor cortex

### • Priming and perceptual:

- Neocortex <sup>clue</sup>

### • Associative learning (classical conditioning):

- Amygdala ✓
- Cerebellum



## 28. All are features of postganglionic lesions, except:

- A. ~~Positive histamine test~~
- B. Good prognosis
- C. Distal to dorsal root ganglion
- D. Surgical repair is possible

Features	<u>Preganglionic</u>	<u>Postganglionic</u>
Site	<u>Proximal</u> to dorsal root ganglion	Distal to dorsal root ganglion
Prognosis	<u>Poor</u>	Good
Histamine test	Positive	<u>Negative</u> (Incomplete)
Surgical repairability	<u>Irreparable</u>	Repairable

*trypsinic*

Central capillary dilatation → surrounding flare → wheal.



181. The serotonergic cell bodies of the analgesia pathway projecting to the dorsal horn of the spinal cord are located in which part of the brain?

A. Periaqueductal gray area - initiates

B. Rostral ventromedial medulla

C. Locus ceruleus - NE

D. Nucleus raphe

(Party)  
-  
Pain

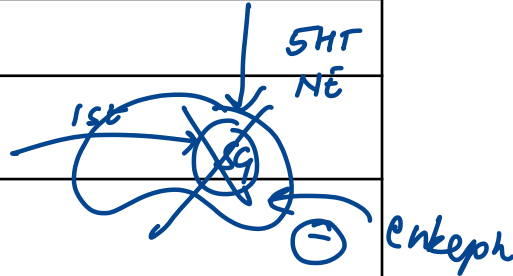
Ascending



Structure	Function
Nociceptors (Aδ, C fibers) 1st o	Detect noxious stimuli (thermal, mechanical, chemical)
Dorsal horn (Lamina I, II – substantia gelatinosa)	First synapse; neurotransmitters: <u>glutamate</u> , <u>substance P</u>
Second-order neurons	Cross midline (anterior white commissure) → ascend in <u>spinothalamic tract</u>
Thalamus ( <u>VPL nucleus</u> )	Relay to cortex
Somatosensory cortex (S1) ← 3rd	Conscious perception of pain

Descending

Structure	Function / Neurotransmitter
<u>Prefrontal cortex</u> , <u>ACC</u>	Modulates perception & emotional response
<u>Periaqueductal gray (PAG)</u>	Activates descending inhibition pathways
<u>Nucleus raphe magnus</u>	Releases <u>serotonin</u> → inhibits pain at spinal level
<u>Locus ceruleus</u>	Releases <u>norepinephrine</u> → inhibits pain
<u>Interneurons in dorsal horn</u>	Release <u>enkephalins</u> , <u>dynorphins</u> → inhibit 1st/2nd order synapse



188. A 5-year-old boy is brought to the emergency department due to recurrent, generalized tonic-clonic seizures over the past 24 hours. He takes no medications and has no family history of epilepsy. The patient's temperature is 39.4 C (103 F), blood pressure is 110/70 mm Hg, pulse is 112/min, and respirations are 10/min. During the examination, the patient suddenly develops sustained, generalized tonic-clonic convulsions without fully regaining consciousness between episodes. Which of the following describes the mechanism of action of the most appropriate initial therapy for his seizures?

- A. Blockade of presynaptic voltage-gated calcium channels
- B. Blockade of presynaptic voltage-gated sodium channels
- C. Enhanced postsynaptic chloride influx
- D. Inhibition of vesicle fusion and neurotransmitter release

↑ GABA



# 190. Which of the following is not a cause of reversible dementia? (INICET MAY 2023)

A. B12 deficiency <sup>R</sup>

B. Normal pressure hydrocephalus <sup>R</sup>

~~C. Lewy body dementia~~ / FTD / AD / vascular / Prion <sup>D</sup>

D. Hypothyroidism <sup>R</sup>

E. SDH

F. Depression

G. TB

H. Pellagra

200. All of the following are features of Balint syndrome except:


A. Denial of blindness

Anton Sx

B. Ocular apraxia

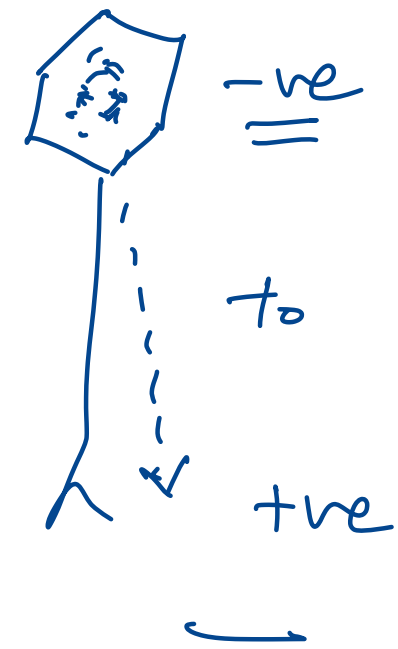
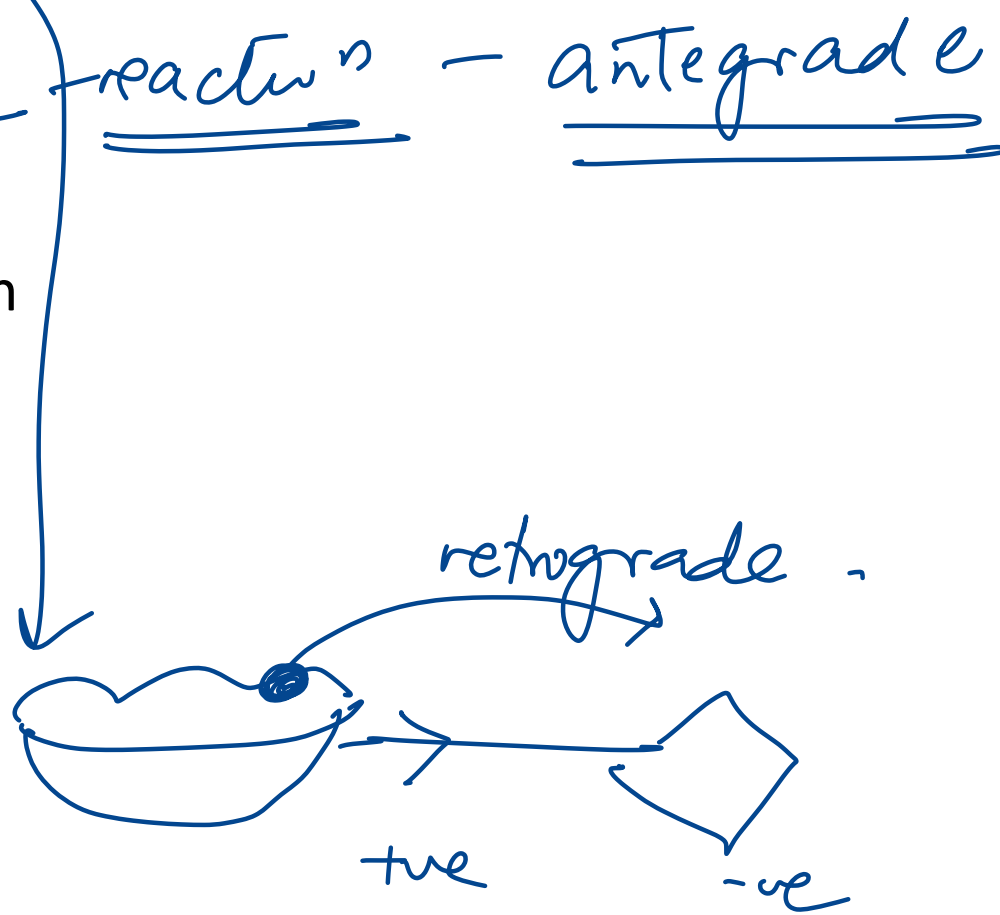
C. Palinopsia

D. Asimultagnosia



146. Upon reactivation of VZV, the virus is transported through the nerve axon to the skin. Which of the following proteins is most likely involved in the transport process leading to disease recurrence?

- A. Dynein
- B. Kinesin
- C. Lamin
- D. Selectin



**162. All of the following are tauopathies, except:**

- A. Pick's disease
- B. Corticobasal degeneration
- C. Progressive supranuclear palsy
- D. REM behavioral disorder = DLB



### **Synucleinopathies:**

- Parkinson's disease
- Dementia with Lewy bodies
- Multiple system atrophy

### **Tauopathies:**

- Alzheimer's disease
- Progressive supranuclear palsy
- Corticobasal degeneration
- Pick's disease
- Chronic traumatic encephalopathy
- Pantothenate kinase-associated degeneration
- Subacute sclerosing panencephalitis (SSPE)
- Down syndrome

# **INTEGRATED RENAL SYSTEM**

---

8. A 27-year-old man comes to the physician because of a 1-day history of fever and joint pains. He is being treated with cephalexin for a skin infection. His urine has turned darker. His temperature is 38.5° C (101.3° F), blood pressure is 125/70 mm Hg, pulse is 90/min, and respirations are 15/min. Examination shows a skin rash; examination otherwise shows no abnormalities. Urinalysis shows: 8 RBCs/HPF, 12 WBCs/HPF with white cell casts, eosinophiluria, and a mild degree of proteinuria. Laboratory studies show a BUN of 40 mg/dl and serum creatinine of 2.2 mg/dl. Which of the following is the most appropriate next step in management?

A. Discontinue cephalexin

B. Start iv fluids

C. Start oral ciprofloxacin

D. Get USG to rule out obstructive uropathy

AIN

## 5. Which of the following about hemodialysis is incorrect?

- A. Predictable ultrafiltration in each session (F)
- B. Urea is cleared more efficiently than creatinine (T) ↑ permeable,
- ~~C. Dialyzer membranes are made up of cellulose membranes~~ biomembranes.
- D. Higher risk of hemodynamic instability than peritoneal dialysis (T)

Hemodialysis	Peritoneal Dialysis CAPD
Comparatively difficult access	Easy access ✓✓
Better clearance	Good clearance
Shorter time for treatment	Longer time may be required
Solute removal via <b>semi-permeable membrane</b>	Solute removal via <u>peritoneal membrane</u>
Must be done in hospital	Can be done at home ✓✓
Hypotension, disequilibrium syndrome, muscle cramps, anaphylaxis	<u>Peritonitis</u> , catheter infections, <u>weight gain</u> , residual uremia, metabolic disturbances

16. A 70-year-old man comes to the OPD due to increasing headaches, nausea, and vomiting. Medical history is significant for a transient ischemic attack that led to a right carotid endarterectomy 5 years ago. Blood pressure is 220/120 mm Hg and pulse is 70/min. Bilateral abdominal bruits are present. Blood testing in this patient would most likely show which of the following?


- A. Low renin, low aldosterone, high angiotensin II, low potassium
- B. High renin, high aldosterone, high angiotensin II, low potassium
- C. Low renin, high aldosterone, high angiotensin II, low potassium
- D. Low renin, low aldosterone, low angiotensin II, high potassium

RAS -LGR  
Renin ↑

35. A 34-year-old man is stranded without water for 36 hours. His urine osmolality is 1100 mOsm/L. Vasopressin plays a major role in concentrating urine. Which part of the nephron responds to vasopressin by absorbing solutes crucial for medullary hypertonicity?

- A. Thin ascending limb of loop of Henle
- B. Cortical collecting duct act
- C. Proximal tubule
- D. Medullary collecting duct
- E. Early distal tubule

urea - ↑ facilitated diffusion



# 192. What differentiates the distal convoluted tubule (DCT) from the proximal convoluted tubule (PCT)?

- A. Presence of carbonic anhydrase in luminal membrane PCT
- B. ~~Lack of  $\text{Na}^+/\text{K}^+$  ATPase in the basolateral membrane~~ PCT
- C. Possession of brush border on luminal membrane PCT
- D. ~~Presence of 'tight' tight junctions~~

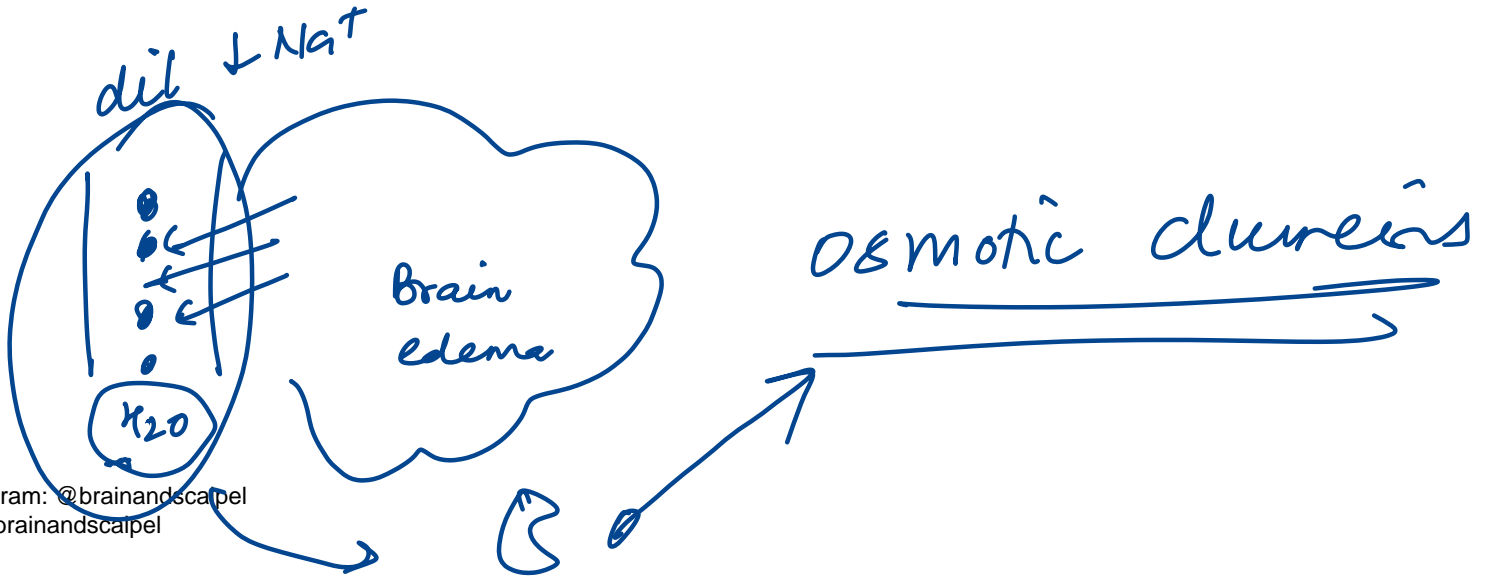
↳ DCT

PCT

'leaky' tight  
↓  
paracellular  
transport.

62. A 62-year-old hypertensive man presents with headache and altered consciousness. CT shows right basal ganglia hemorrhage with midline shift. Mannitol is given IV. What is the expected acute effect of this medication?

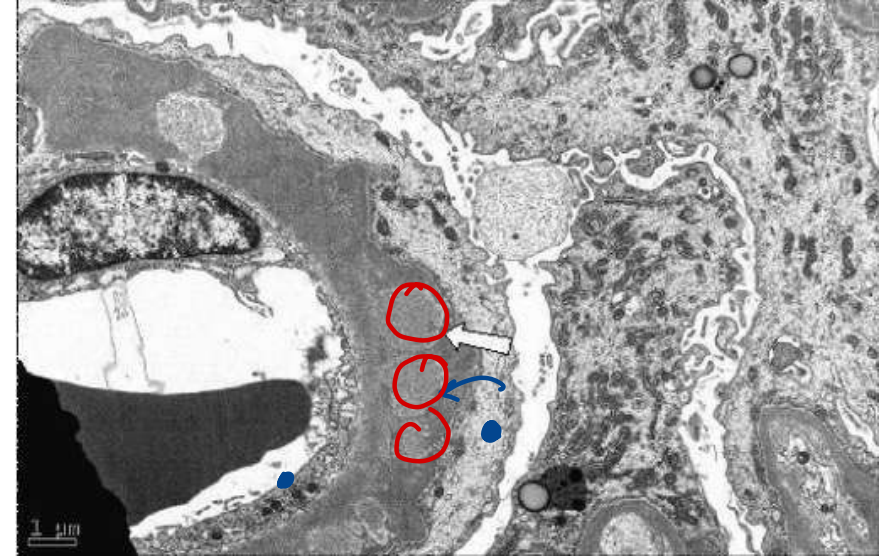
- A. Serum sodium ↓, Tubular flow ↑, Filtrate osmolality ↑
- B. Serum sodium ↓, Tubular flow ↓, Filtrate osmolality ↓
- C. Serum sodium ↑, Tubular flow —, Filtrate osmolality ↑
- D. Serum sodium —, Tubular flow ↓, Filtrate osmolality ↑



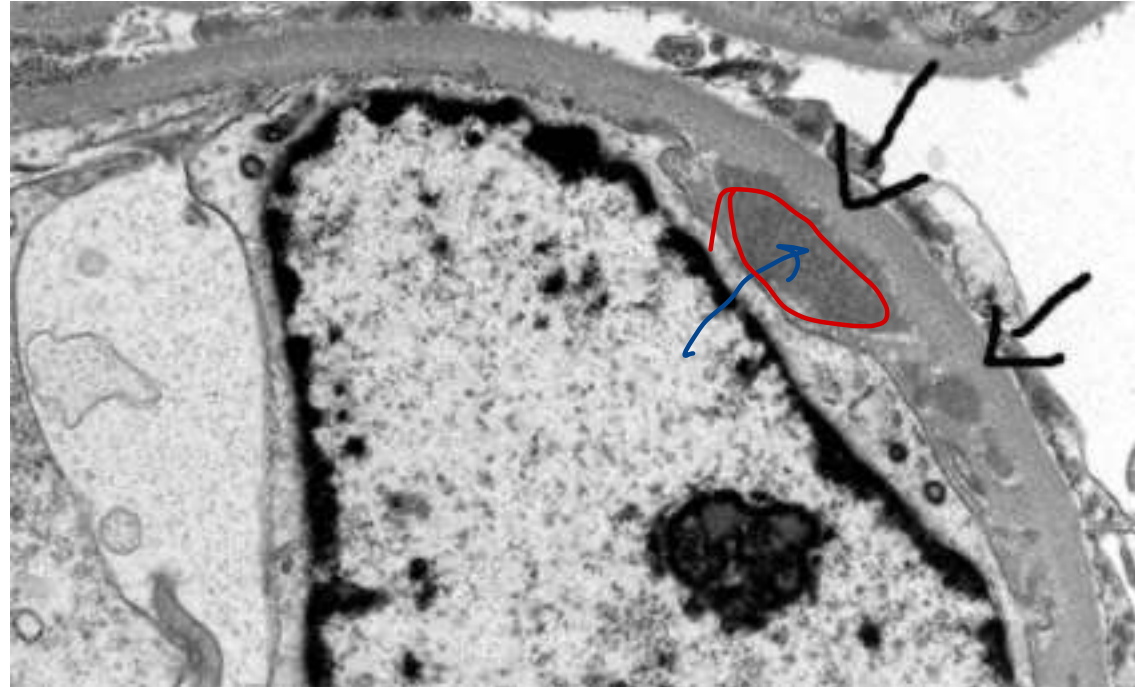
CT in p. edema  
in axons

86. Given below is an electron microscopy image showing deposits in the kidney. What could be the diagnosis?

- A. Goodpasture syndrome
- B. Membranoproliferative glomerulonephritis
- C. Membranous nephropathy
- D. Minimal change disease



*subepithelia*



Subendo

139. A new aminoglycoside antibiotic is developed that is believed to be particularly effective against *Pseudomonas*. The volume of distribution of the drug is measured in a group of volunteers and is determined to be 4.5 L. This new drug is most likely to have which of the following properties?

- A. It has low molecular weight
  - B. It is lipophilic
  - C. It does not bind to albumin
  - D. It is highly charged
- Handwritten notes: A red arrow points from the underlined '4.5 L' in the question to the underlined 'It is highly charged' in option D. Another red arrow points from the underlined 'It is highly charged' to the circled '9' in option C. A circled '9' is also present next to option C. The text '↑ Vd' is written in red next to the arrow pointing to option D.

Low Vd



## 145. Which substance leads to relaxation in mesangial cells?

- A. PGF2
- B. Endothelin
- C. Vasopressin
- D. cAMP

Relaxation

Dopamine

ANP

cAMP

PGE2

DANCE 2

# **INTEGRATED ENDOCRINE SYSTEM**

---

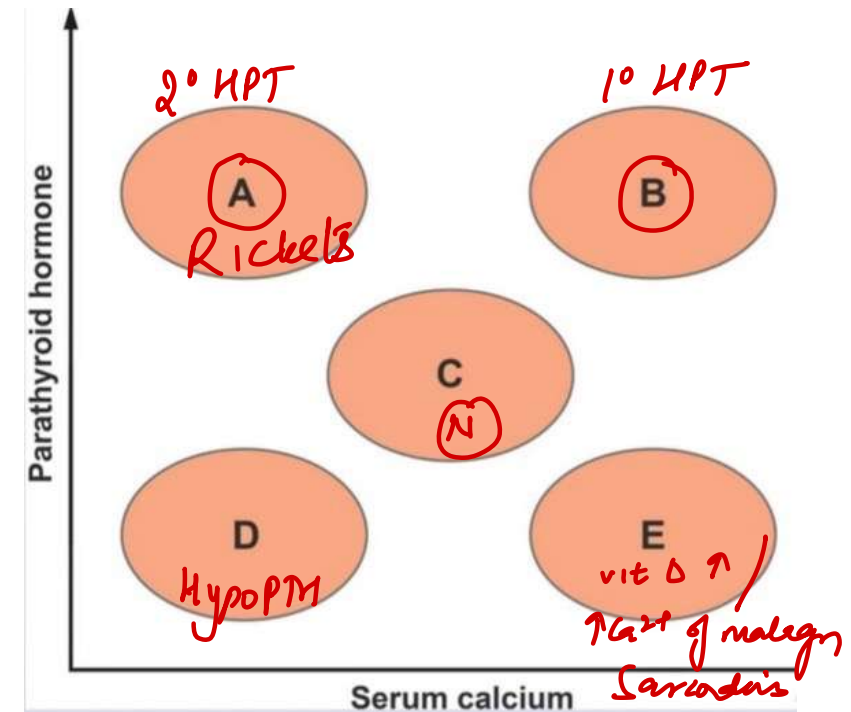
58. A 64-year-old man comes to the OPD with fatigue. He has hypertension and poorly controlled diabetes complicated by nephropathy and peripheral neuropathy. His renal function has declined steadily over the last few years. On the graph below, area "C" shows the normal relationship between serum concentrations of free calcium and parathyroid hormone. Which of the following areas most likely represents this patient's current metabolic state?

A. A

B. B

C. C

D. E



75. A 44-year-old man has fatigue, insomnia, palpitations, and 9 kg weight loss. TSH is low, free thyroxine is high, thyroid diffusely enlarged, and TSH receptor antibodies are positive. Which of the following findings would be most specific for this patient's pathophysiologic process?

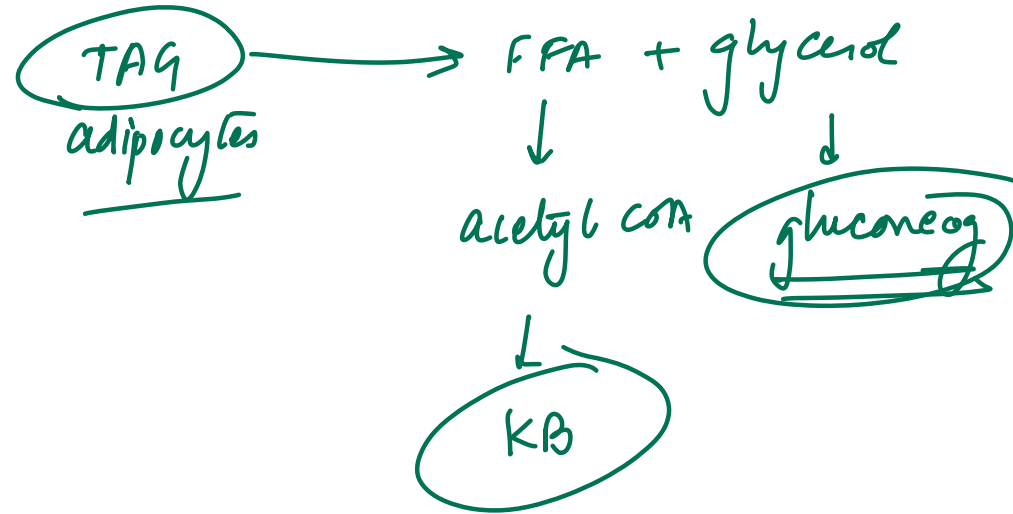
- A. Atrial fibrillation
- B. Decreased bone mineral density
- C. Skin thickening and induration over the shin
- D. Tremor of the outstretched hands

Graves

pretibial myxedema  
Graves

80. A 72-year-old woman is found after lying on the floor for 2 days. She has dehydration, urine ketones, serum glucose 72 mg/dL, and a femoral neck fracture. Which enzyme's increased activity is most likely contributing to both serum and urine findings?

- A. Glycogen phosphorylase
- B. Hormone-sensitive lipase *HL*
- C. Lipoprotein lipase
- D. Phosphofructokinase-1



90. A 29-year-old man presents with headaches, fatigue, visual disturbances. He has sarcoidosis, mild hypercalcemia, and MRI shows mass in hypothalamus and pituitary stalk. Which of the following pituitary hormones is most likely elevated in this patient?

- A. ACTH
- B. Growth hormone
- C. Prolactin  $\uparrow$
- D. Thyrotropin

Dopa xx  $\ominus$  PRL

99. A 54-year-old woman presents for evaluation of elevated blood glucose. BMI is 31.5 kg/m<sup>2</sup>. HbA1c is 8.5% and fasting plasma glucose is 146 mg/dL. She is planned to start metformin. Which of the following laboratory tests should be obtained prior to starting this medication?

A. Blood cell counts and mean corpuscular volume

B. Oral glucose tolerance test

C. Plasma lactate level ~~XX~~

D. Serum creatinine level

*Uremia*

*Lactic acidosis*

## Metformin

### Activates:

- **AMP-activated protein kinase (AMPK)** →
  - ↑ Acetyl-CoA carboxylase phosphorylation → ↓ Lipogenesis
  - ↓ Gluconeogenic gene expression → ↓ Gluconeogenesis

### Inhibits:

- **Mitochondrial GPD (Glycerol-3-Phosphate Dehydrogenase)** →
  - ↓ Glycerol availability → ↓ Gluconeogenesis
  - ↓ Pyruvate →
    - ↑ NADH
    - Pyruvate is diverted to Lactate via **LDH (Lactate Dehydrogenase)** →  
→ Lactic acidosis

glycolysis

103. A 34-year-old woman reports irregular menstruation and 4.5 kg weight gain over 6 months. BP is 152/86 mmHg, BMI is 31 kg/m<sup>2</sup>. Physical exam shows abdominal and supraclavicular fat accumulation, hyperpigmentation in skin creases, and wide abdominal striae. Which of the following sets of laboratory findings are most likely to be seen in this patient?

- A. ↑ 24-hour urinary cortisol, ↑ ACTH, ↑ DHEAS
- B. ↓ 24-hour urinary cortisol, ↑ ACTH, ↓ DHEAS
- C. ↑ 24-hour urinary cortisol, ↓ ACTH, Normal DHEAS
- D. Normal 24-hour urinary cortisol, Normal ACTH, ↑ DHEAS

ACTH ↑  
↓  
Cortisol ↑  
DHEAS ↑

Permissive action of

epinephrine

124. A 45-year-old woman comes to the OPD for follow-up of type 2 diabetes mellitus. The patient is taking the maximum dose of metformin. Her hemoglobinA1c is 7.7%. Blood pressure is 134/86 mm Hg, and pulse is 72/min. BMI is 33 kg/m<sup>2</sup>. Family history is significant for osteoporosis in mother. The results of other laboratory tests are normal. After discussion, a sodium-glucose cotransporter-2 inhibitor is added to the patient's drug regimen. Which of the following is the most likely additional effect of the newly prescribed medication?

A. Decreased blood pressure

B. Increased bone mineral density

C. Increased fluid retention

D. Increased postprandial satiety

↓ intravascular vol

**186. A patient suffering from hyperthyroidism is administered a drug that acts by inhibiting the release of thyroid hormone. Identify the drug.**

- A. Propylthiouracil
- B. Radioactive iodine
- C. Thiocyanate
- D. Potassium iodide**

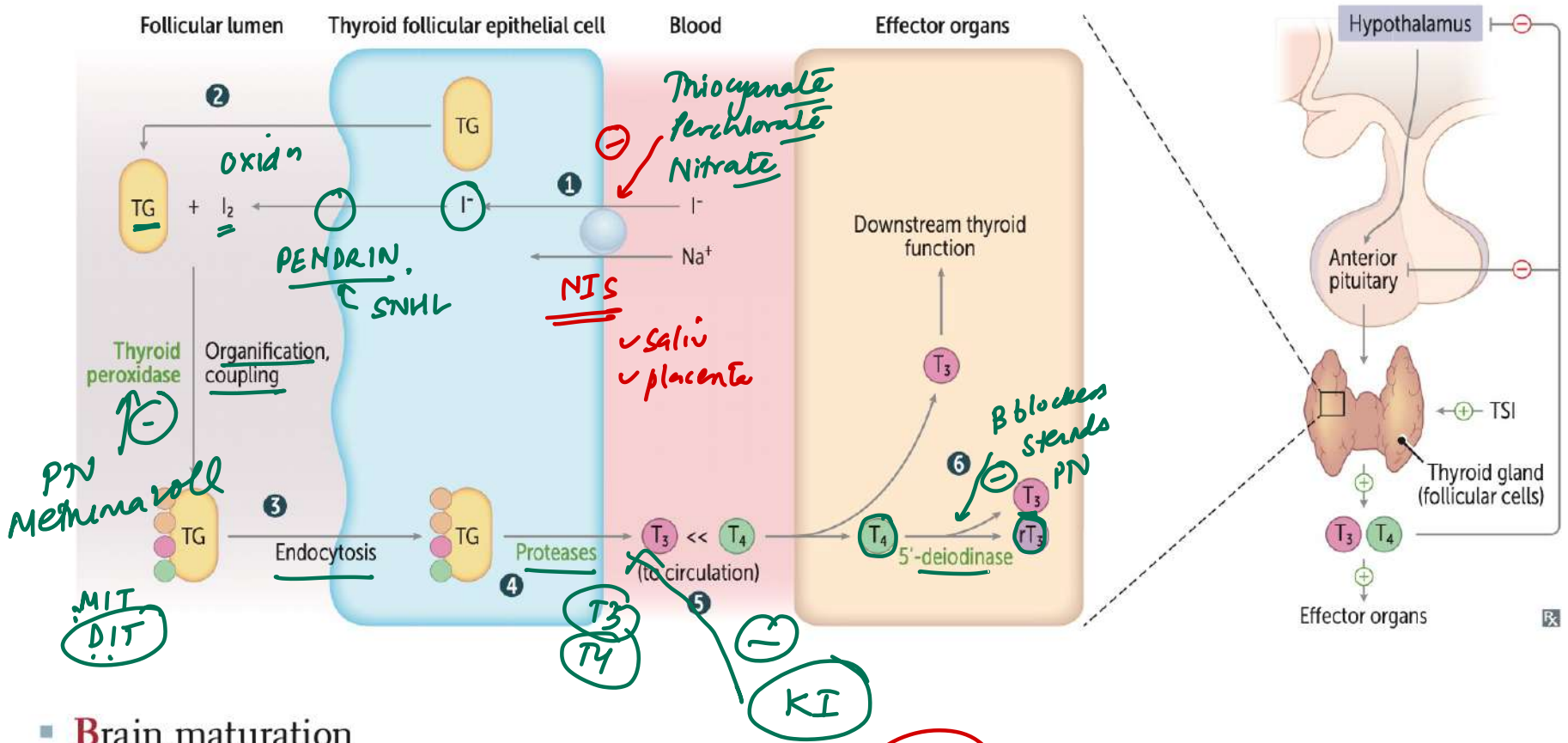
196. A woman presents with signs of hyperthyroidism. Which feature is not typically associated with her condition?

- ~~A. Reduced protein breakdown~~
- B. Increased heart rate
- C. Decreased peripheral vascular resistance
- D. Increased stroke volume

↑ metab

↑ catab

↑ β



- Brain maturation
- Bone growth (synergism with GH and IGF-1) *vd - ↓PVR*
- β-adrenergic effects.  $\uparrow \beta_1$  receptors in heart  $\rightarrow \uparrow$  CO, HR, SV, contractility; β-blockers alleviate adrenergic symptoms in thyrotoxicosis
- Basal metabolic rate  $\uparrow$  (via  $\uparrow$  Na<sup>+</sup>/K<sup>+</sup>-ATPase  $\rightarrow \uparrow$  O<sub>2</sub> consumption, RR, body temperature)
- Blood sugar ( $\uparrow$  glycogenolysis, gluconeogenesis)
- Break down lipids ( $\uparrow$  lipolysis) *Catabolic P*
- Stimulates surfactant synthesis in Babies

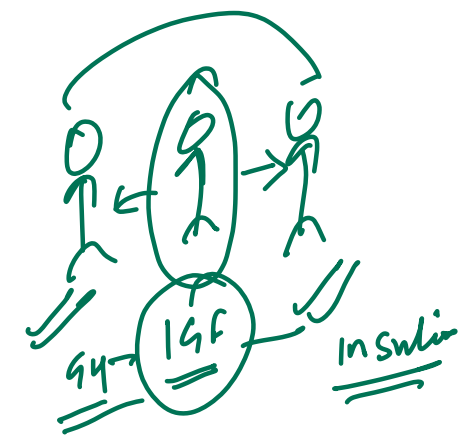
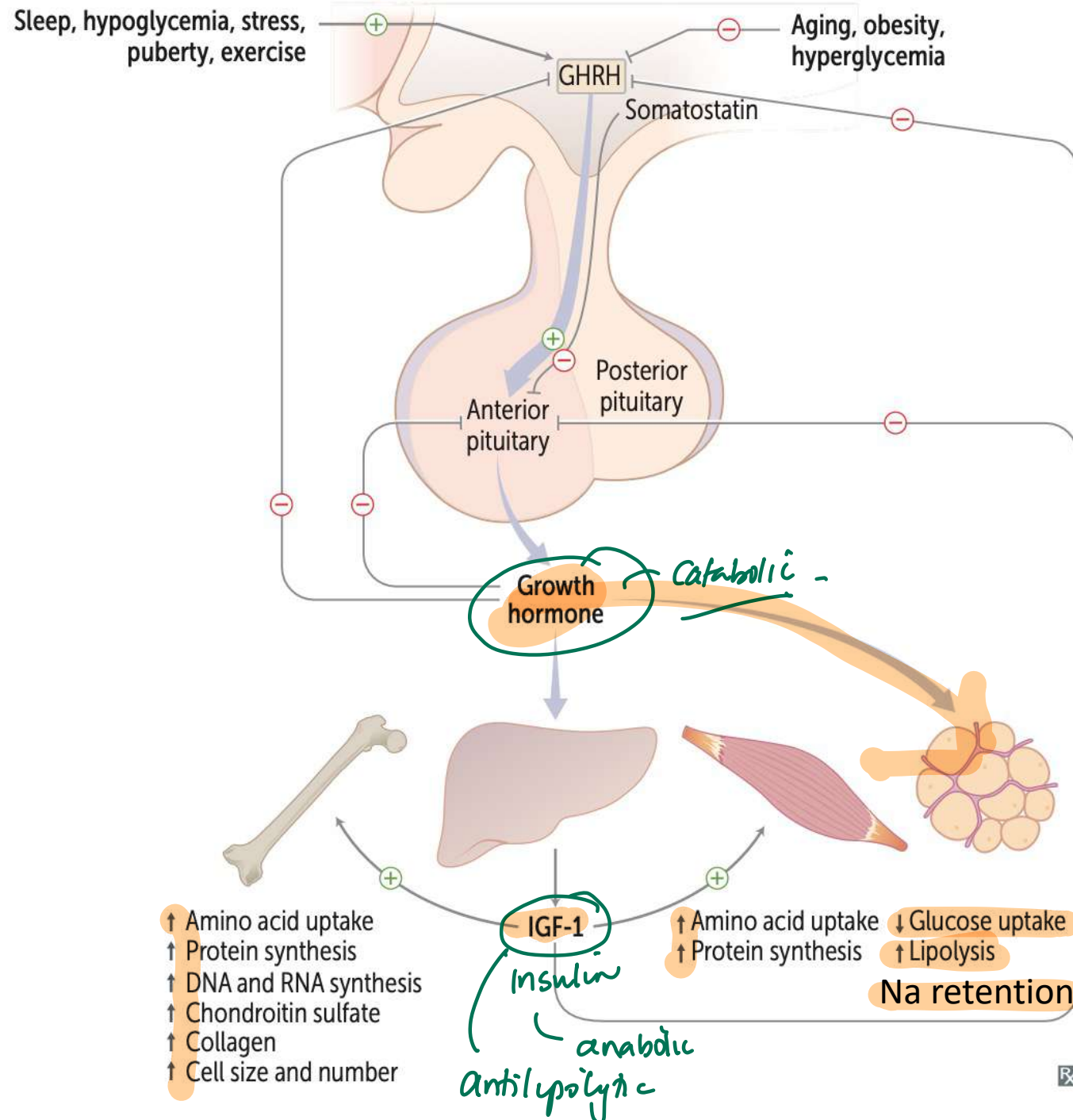
## 194. Regarding thyroid storm, which statement is false?

- A. Mortality is ~~10%~~ despite treatment 30%!
- B. It may follow non-thyroid surgeries
- C. Symptoms can include diarrhea, vomiting, jaundice, and confusion
- D. High-dose propranolol can reduce T4 to T3 conversion

DOC: PTU

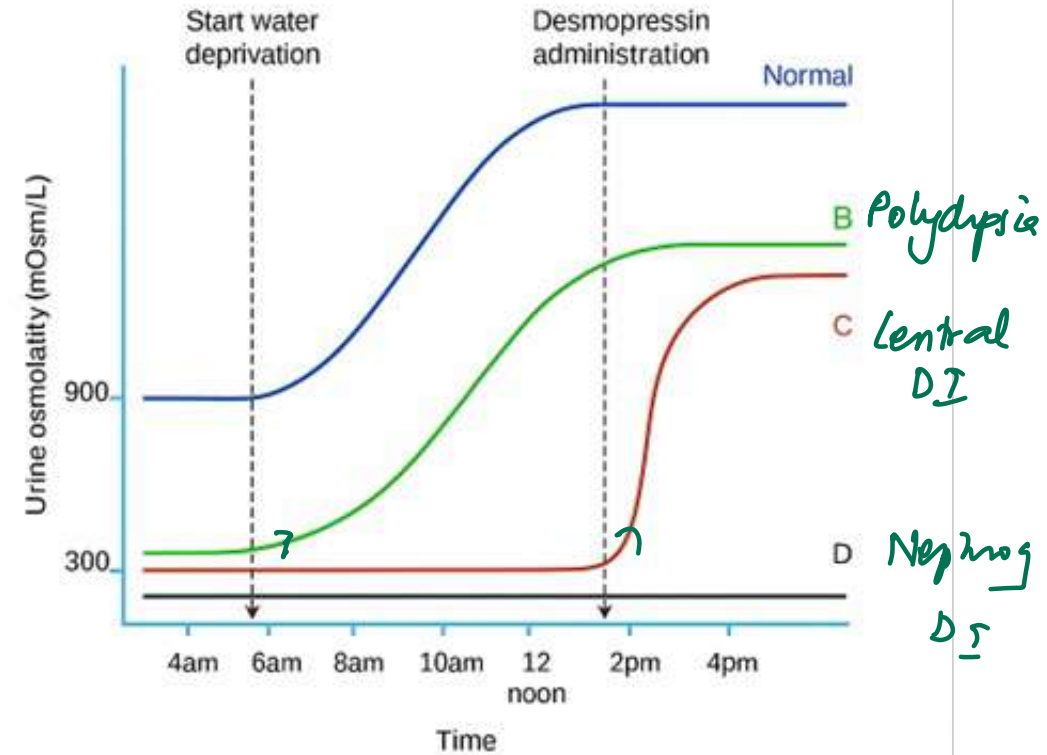
159. Which function of growth hormone (GH) is specifically mediated via IGF-1?

- A. Sodium retention
- B. Lipolysis
- C. Reduced insulin sensitivity
- D. Antilipolysis



# 121. Identify the correct pair?

- A. B-Normal
- B. C- Primary polydipsia
- C. D-Nephrogenic DI**
- D. B-Central DI



# 189. Highest mineralocorticoid activity is seen with which of the following?

A. Aldosterone

B. DOCA

C. Fludrocortisone

D. Triamcinolone

gc action

↑ mc - synthetic

Dexa

Beta

↓

max gc

Hydrocortisone

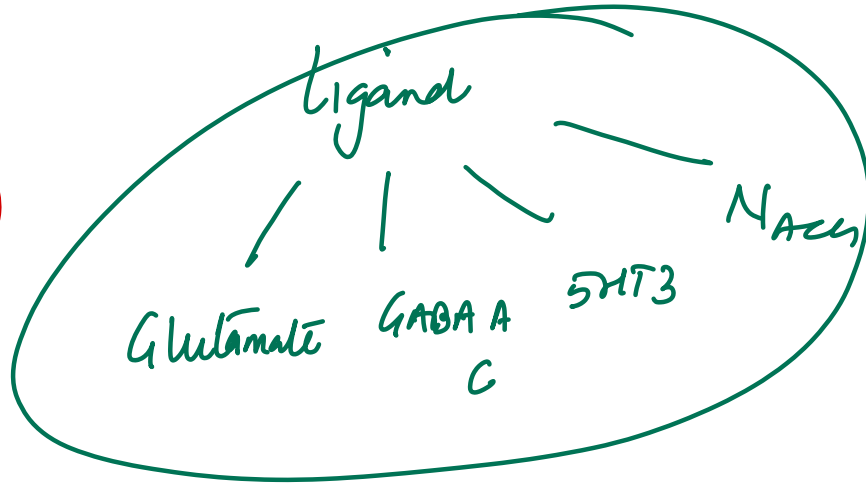
↳ CAM

both - gc ↑ mc

163. Match the neurotransmitter with its <sup>in</sup> correct receptor type:

- A. GABA-A – Ionotropic
- B. Glycine – G-Protein Coupled Receptor
- C. Nicotinic – G-Protein Coupled Receptor
- D. ~~GABA-B – Ionotropic~~

GPCR



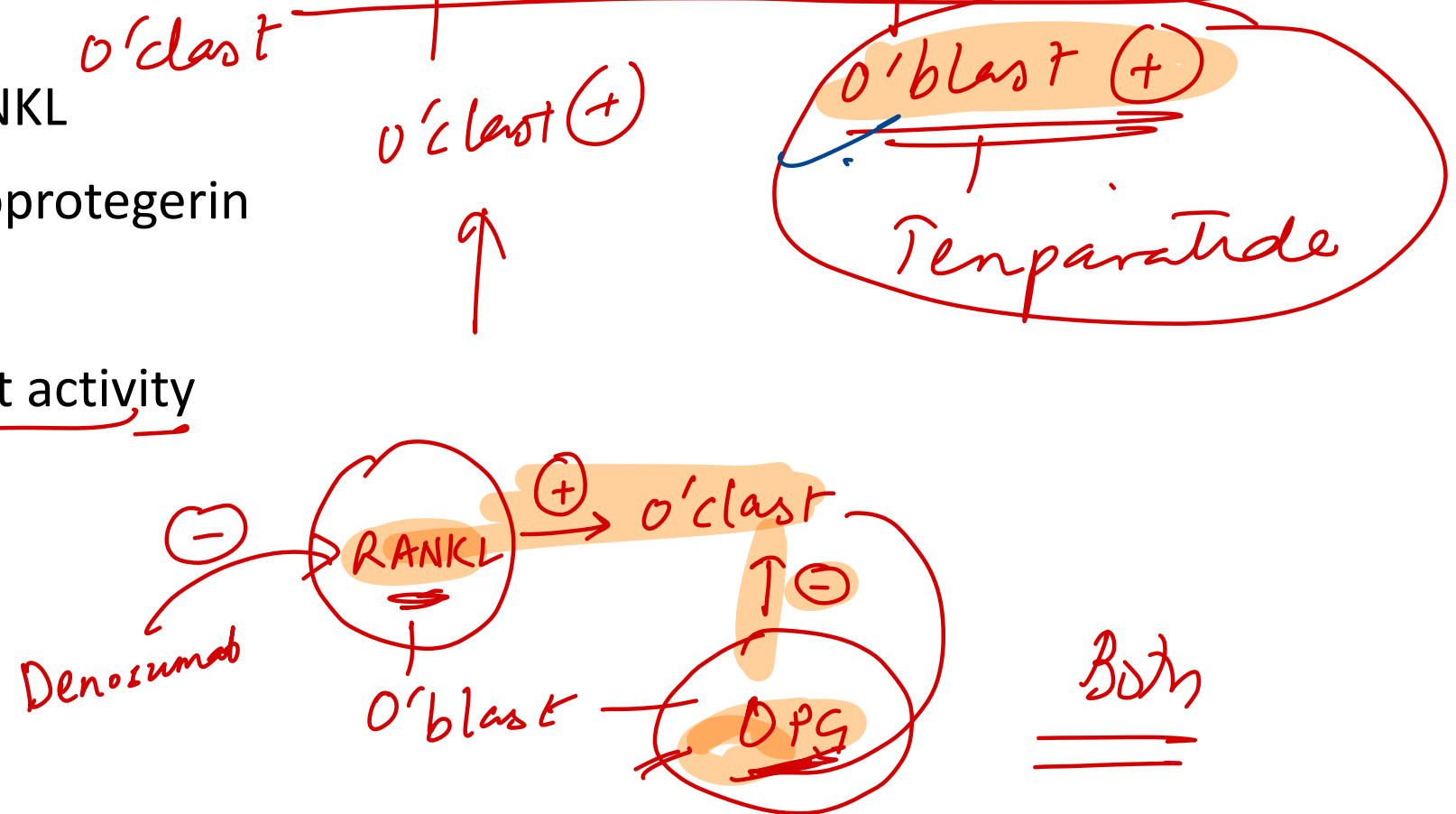
Neurotransmitter	Receptor Type
Glutamate	- Ligand-gated ion channels: NMDA, AMPA
GABA	- Ligand-gated: GABA A, GABA C
Acetylcholine	- Nicotinic → Ligand-gated
<u>Norepinephrine, 5HT,</u> <u>Dopamine, AchM</u> <u>GABA-B</u> $\alpha\phi$ <u>Glycine</u>	GPCR (except 5HT3 which is ligand-gated)

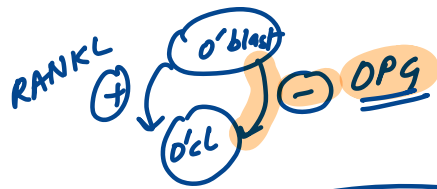
} Ligand gated

$G_q$  -  $H_{\alpha V_1}$ ,  $M_1$ ,  $M_3$   
 $G_s$  -  $B$   
 $G_i$  -  $M_2$ ,  $\alpha_2$ , D2

133. A study is conducted to assess the effect of parathyroid hormone (PTH) on bone remodeling. Half of the study subjects receive intermittent PTH injections and the other half receive a continuous infusion of PTH. The results show that the effects on bone metabolism of intermittent PTH injections are different from those of continuous infusion. Which of the following is most likely to be the predominant bone effect with intermittent injections?

- A. Increased activity of RANKL
- B. Increased levels of osteoprotegerin
- C. Osteoclast apoptosis
- D. Stimulation of osteoblast activity





Temperature : o'blast (+)

# Integrated GI / HPB

---

92. A 54-year-old man with epigastric pain and positive occult blood test undergoes endoscopy, revealing hyperemic nodular mucosa. Biopsy shows submucosal glands producing alkaline mucus. Which part of the GI tract was biopsied?

A. First part of the duodenum

B. Mid-jejunum

C. Antrum of the stomach

D. Terminal ileum

*Brunner's*

### 93. Which of the following is not a histopathological feature of the liver in chronic Hepatitis B

A. Bridging necrosis and fibrosis ✓

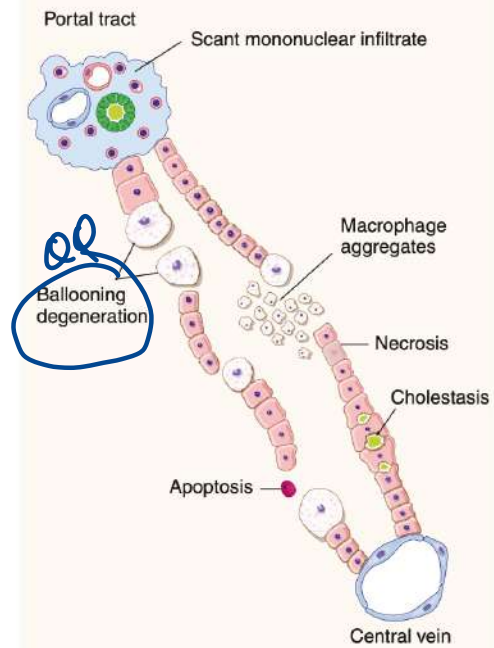
B. Ground-glass hepatocytes ✓

C. Ballooning degeneration

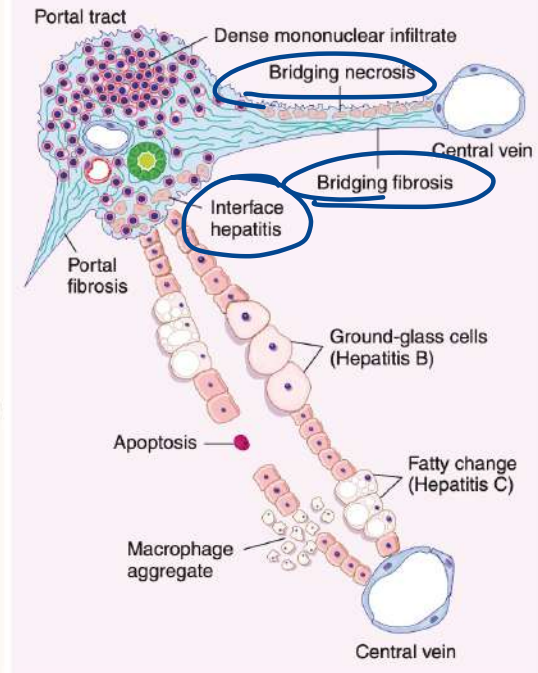
*acute*

D. Piecemeal necrosis = *Interface* ✓

### ACUTE HEPATITIS

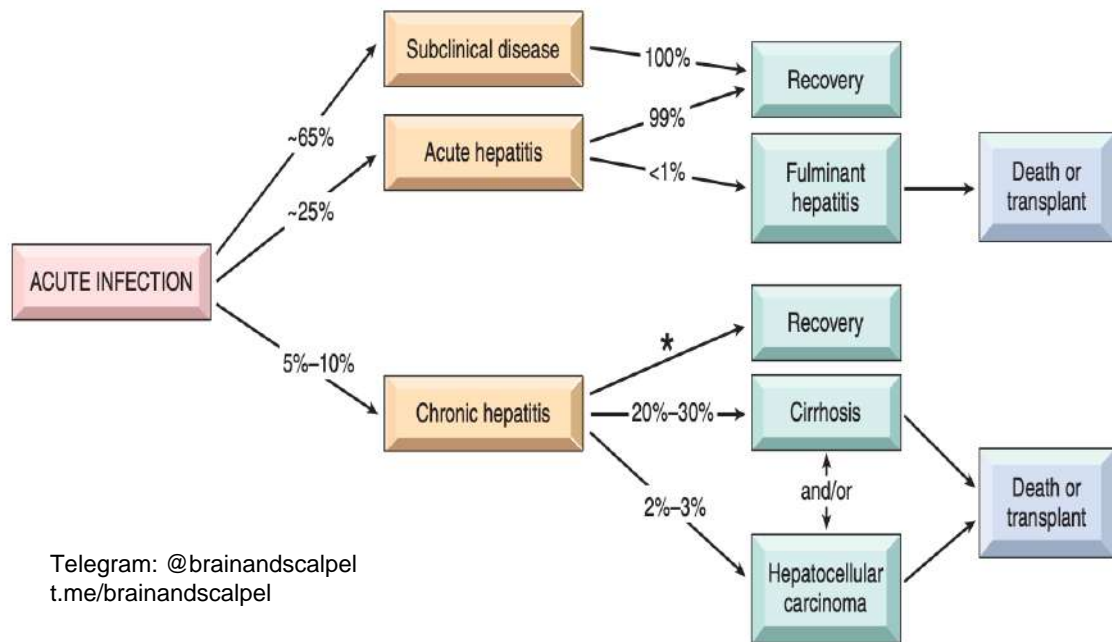


### CHRONIC HEPATITIS



**Table 14.2** The Hepatitis Viruses

Virus	Hepatitis A (HAV)	Hepatitis B (HBV)	Hepatitis C (HCV)	Hepatitis D (HDV)	Hepatitis E (HEV)
Viral genome	ssRNA	Partially dsDNA	ssRNA	Circular defective ssRNA	ssRNA
Viral family	Hepadnavirus; related to picornavirus	Hepadnavirus	Flaviviridae	Subviral particle in Deltaviridae family	Hepeviridae family, <i>Hepevirus</i> genus
Route of transmission	Fecal-oral (contaminated food or water)	Parenteral, sexual contact, perinatal	Parenteral; intranasal cocaine use is a risk factor	Parenteral	Fecal-oral
Incubation period	2–6 weeks	2–26 weeks (mean 8 weeks)	4–26 weeks (mean 9 weeks)	Same as HBV	4–5 weeks
Frequency of chronic liver disease	Never	5%–10%	>80%	10% (coinfection); 90%–100% for superinfection	In immunocompromised hosts only
Diagnosis	Detection of serum IgM antibodies	Detection of HBsAg or antibody to HBcAg; PCR for HBV DNA	ELISA for antibody detection; PCR for HCV RNA	Detection of IgM and IgG antibodies, HDV RNA in serum, or HDVAg in liver biopsy	Detection of serum IgM and IgG antibodies; PCR for HEV RNA



In contrast to HBV, chronic disease occurs in the majority of individuals infected with HCV (80%–90%), and cirrhosis eventually occurs in approximately 20% over a period of 20 to 30 years.

109. A 1-month-old infant, born at 35 weeks gestation, presents with blood-streaked, mucous-filled diarrhea after taking a standard cow's milk-based formula. Symptoms resolved upon switching the formula. If a biopsy was performed during the symptomatic period, which of the following histological findings would most likely be observed?

- A. Neutrophilic crypt abscesses in the colon
- B. Eosinophilic infiltration in the distal colon
- C. Hemorrhagic necrosis of the intestinal wall
- D. Presence of heterotopic gastric mucosa in the distal ileum

## Food Protein–Induced Allergic Proctocolitis

### Pathophysiology

- Non-IgE-mediated reaction
- Eosinophilic inflammation of rectosigmoid colon
- Common triggers: cow's milk & soy protein

### Clinical Features

- Age: 1–4 weeks (can be up to 6 months)
- Well appearing
- Blood- and/or mucus-streaked stools (positive Hemocult)

**185. All are components of MELD 3.0 score, except:**

- A. INR
- B. Female sex
- C. ~~Platelet count~~
- D. Creatinine

CBI / Na<sup>+</sup> / ♀  
alb

Letter	Parameter
S	Serum sodium (mEq/L) ✓ d'o
A	Albumin ✓
B	Bilirubin ✓
R	Renal function (Creatinine) ✓
I	INR (International Normalized Ratio) ✓
C	Category: Female sex ✓

**152. During fasting, which hormone is secreted by the stomach to enhance hunger?**

A. CCK

B. Leptin

C. Ghrelin

D. Orexin

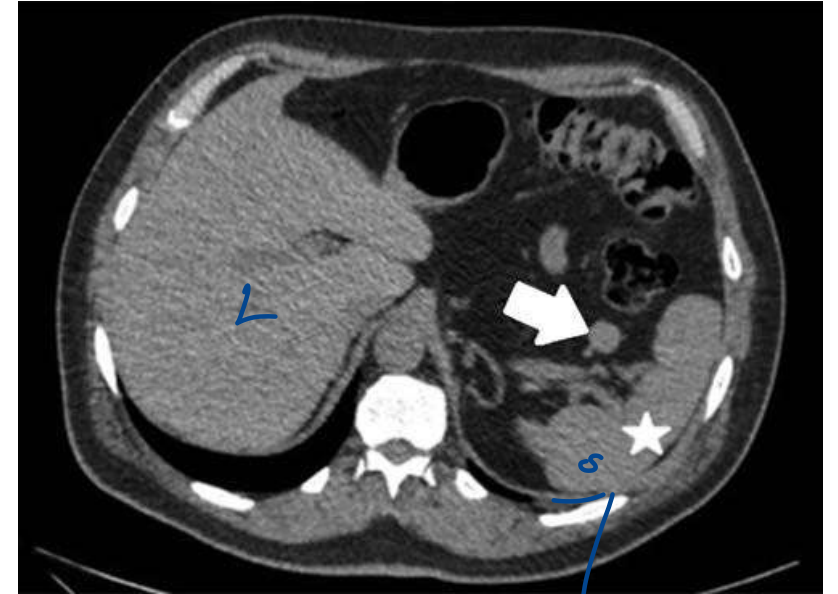
72. A CT scan shows a structure indicated by an arrow. This organ shares embryologic origin with which of the following tissues?

A. Skeletal muscle

B. Liver

C. Adrenal medulla

D. Thymus



# **INTEGRATED RESPIRATORY SYSTEM**

---

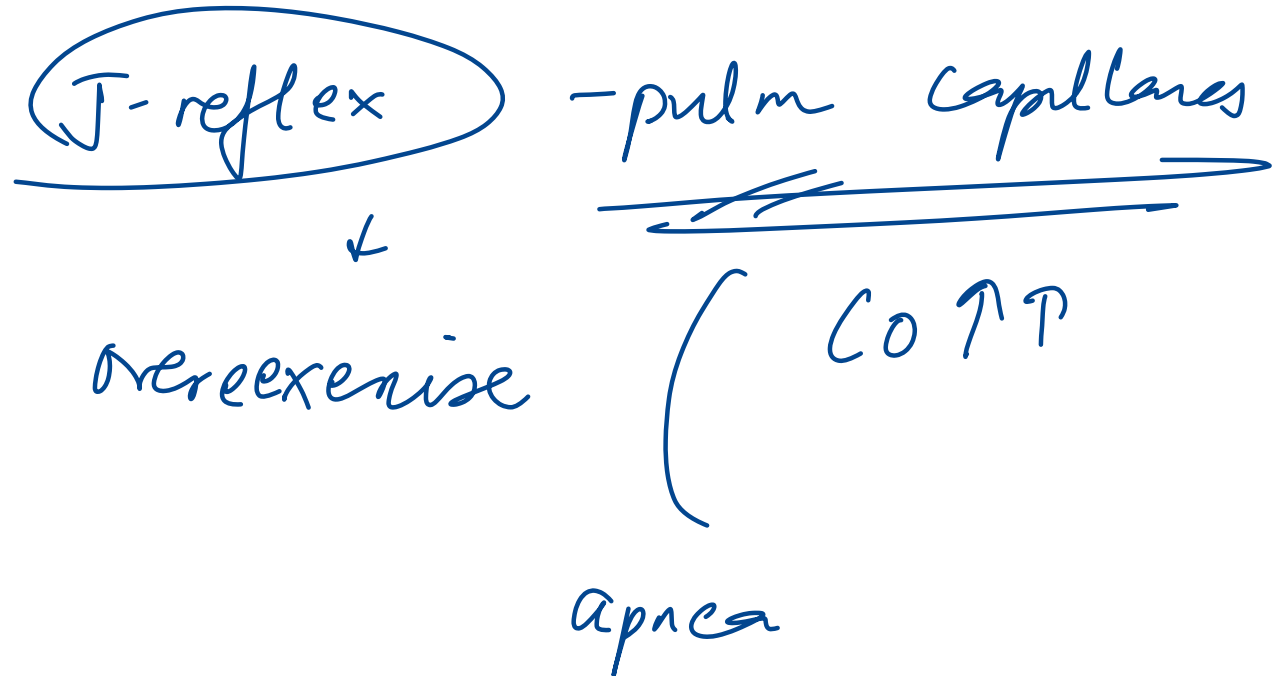
177. During adaptation to high altitude, which of the following does not occur?

- A. Increase in peripheral chemoreceptor sensitivity
- B. Increase in central chemoreceptor sensitivity
- C. ~~Leftward~~ shift of oxygen dissociation curve
- D. Increase in minute ventilation

RT

## 56. All are advantages of the Hering-Breuer reflex, except:

- A. Prevents overinflation during deep inspiration ✓✓
- ~~B.~~ Promotes high lung volumes for efficient gas exchange
- C. Prevents atelectasis during expiration
- D. Reduces unnecessary energy expenditure



# 71. All of the following increase lung compliance, except:

A. Pulmonary emphysema ↑


B. Normal aging ↑

~~C. Inspiration~~

D. Saline-filled lung inflation

↑

Surfactant conc



insp ↓

exp ↑ - comp

129. What is the Global Initiative for Asthma (GINA)'s recommendation regarding the use of long-acting  $\beta$ 2-agonists (LABA)?

A. In combination with a short-acting  $\beta$ 2-agonist

B. Inhaled alone

C. With an inhaled corticosteroid ↓inflamm?

D. With an inhaled anticholinergic agent

126. A 36-year-old woman is referred for evaluation because of hematuria and haemoptysis since 2 weeks. DLCO is 120% of normal with normal lung volumes. What is the likely diagnosis in this patient?

- A. Pulmonary hypertension ~~XX~~
- B. Asthma ~~XX~~
- C. Wegener's granulomatosis ~~✓~~ *avortay -*
- D. ~~Microscopic polyangiitis~~ *✓*

*Pulm hge*

131. Which of the following is the most appropriate treatment for COPD in a patient with dementia?

- A. Tolterodine <sup>anticholinergic</sup> (UB)
- ~~B. Tiotropium~~ COPD (x BBB)
- C. Telenzepine MI ⊖
- D. Tropicamide cyclop + mydriasis

# **INTEGRATED RHEUMATOLOGY**

---

**198. A patient with gout develops hypertension. Which of the following drugs is not administered?**

~~A. Hydrochlorothiazide~~

B. Atenolol

C. Enalapril

D. Prazosin

Letter	Drug
P	Pyrazinamide <span style="margin-left: 20px;">↑ URICEMIA</span>
A	Aspirin (low dose) ✓✓
I	Immunosuppressants (e.g., cyclosporine)
N	Niacin ✓✓ <span style="margin-left: 20px;">—————→</span>
T	Thiazide diuretics ✓✓
C	<u>Chemotherapy (cancer drugs)</u>
E	Ethambutol
L	Lasix (furosemide) ✓✓

154. Two weeks after being treated for nongonococcal urethritis, a 34-year-old man develops acute conjunctivitis, right-knee pain, and vesicular lesions on his palms and soles. This syndrome is most strongly associated with which of the following?

- A. Sacroiliitis
- B. Polymyositis
- C. Esophageal dysmotility
- D. Hyperparathyroidism

Reiter Sx

ank spond

IBD associated.

psomatic

# GENERAL PATHOLOGY

---

15. A 7-year-old boy has difficulty walking. Exam shows pes cavus, scoliosis, and a systolic murmur at left sternal border. Which is incorrect regarding this condition?

HOCM.

- A. Expansion of a GAA trinucleotide repeat
- B. Presence of extensor plantar reflex
- C. ~~Association with chromosome 19~~
- D. Autosomal recessive inheritance

9

C/S

+

Spinocerebellar

+

DC tract

2. A woman develops wheezing after taking aspirin for a headache. Which statement is true about this condition?

- A. A type of extrinsic asthma ~~X~~
- B. Raised serum IgE levels ~~X~~
- C. Associated with ethmoid polyps ✓
- D. ~~Positive skin test for inhaled allergens~~

Sampter's  $\Delta$

Extrinsic Asthma	Intrinsic Asthma
Atopic / allergic asthma	Non-atopic / non-allergic / idiosyncratic asthma
Atopy, drug or food allergy	Samter's triad
Childhood	Adult
Eosinophil mediated	Neutrophil mediated
↑ IgE (Type I hypersensitivity)	Normal IgE (negative skin prick test)
Responds well to inhaled corticosteroids	Decreased short-term response
Good prognosis	Bad


## 52. What type of collagen is involved in the classic Ehlers-Danlos syndrome?

A. Type 1

B. Type 2

C. Type 5

D. Type 4

EDS Type	Clinical Findings	Inheritance	Collagen/Protein Type
<u>Classic (Type I/II)</u>	Skin & joint hypermobility, atrophic scars, easy bruising	Autosomal dominant	<u>Collagen type 5</u>
Hypermobility (Type III)	Joint hypermobility, pains, dislocations	Autosomal dominant	—
Vascular (Type IV)	Thin skin, <u>arterial/uterine</u> rupture, small-joint hyperextensibility	Autosomal dominant	Collagen type 3 
<u>Kyphoscoliosis (Type VI)</u>	Hypotonia, scoliosis, ocular fragility	<u>Autosomal recessive</u>	<u>Lysyl hydroxylase-1</u>
Arthrochalasia (Type VII a,b)	Severe joint hypermobility, mild skin changes, scoliosis, bruising	Autosomal dominant	Collagen type 1 <u>  </u>
<u>Dermatosparaxis (Type VII c)</u>	Severe skin fragility, cutis laxa, bruising	<u>Autosomal recessive</u>	<u>Procollagen N-peptidase</u>

39. Patients with all of the following conditions have ER-positive and HER2-negative tumors except:

A. Lobular carcinoma


B. Tubular carcinoma

C. Mucinous carcinoma

~~D. Basal type carcinoma~~

TNBC

Luminal A



### 43. Which of the following is incorrect regarding the BRCA genes?

- A. BRCA1 is located on the long arm of chromosome 17 T
- B. BRCA1 mutation causes well-differentiated cancer
- C. BRCA2 carcinomas are Luminal A type
- D. BRCA2 mutation is associated with male breast carcinoma

Feature	BRCA1	BRCA2
Location	Long arm of chromosome 17	Long arm of chromosome 13
Differentiation	Poorly differentiated	Well-differentiated
Hormone receptor status	triple negative	ER/PR-Positive
Associated cancers	Breast, ovarian, colon	Breast, ovarian, colon, prostate, pancreas, gall bladder, stomach cancers, melanoma
Male breast carcinoma	Low risk	Increased risk
Fanconi's anemia	Not associated	Associated

HEJ

195. All streptococcal antigen–host antigen–disease associations are true, except:

Molecular mimicry  
Strep

- A. M protein – Myocardium – ARF
- B. Cytoplasmic membrane – Glomerular intima – PSGN
- C. Peptidoglycan – Skin antigens – Guttate psoriasis
- ~~D. Hyaluronic acid – Skin – Impetigo~~
- Jt      arthralgia

143. A 62-year-old woman has a 3-month history of painful, swollen wrists and knees with morning stiffness. Imaging shows joint space narrowing and marginal erosions. Which cytokines are chiefly responsible for her joint destruction?

A. Interleukin-1 and tumor necrosis factor- $\alpha$

B. Interleukin-10 and transforming growth factor- $\beta$  - anti inf -

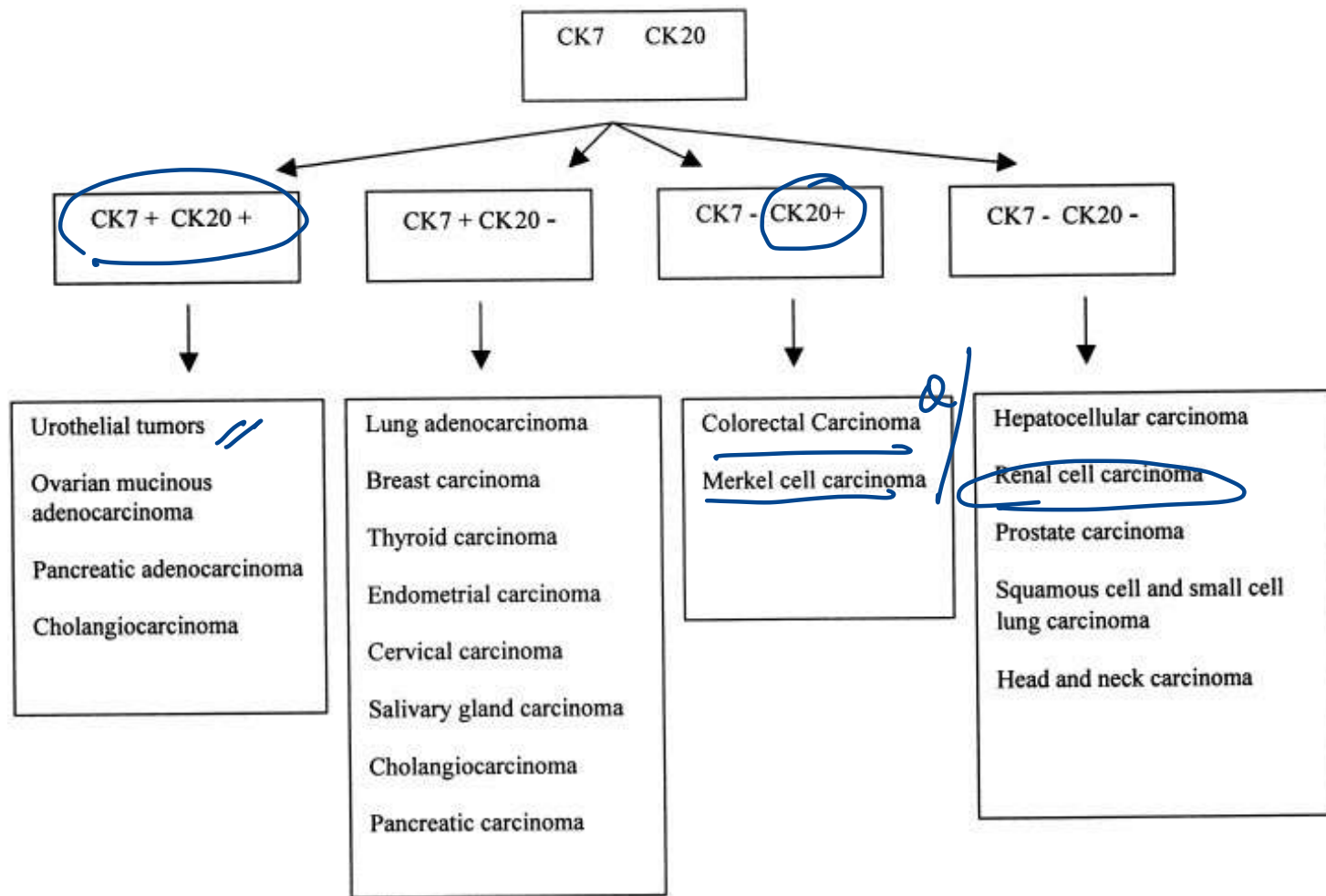
C. Interleukin-2 and interferon- $\gamma$  granulomas

D. Interleukin-4 and interleukin-5 Humoral.

RA

**130. Which of the following pairs correctly describes the immunohistochemical property of renal cell carcinoma?**

- A. CK7 positive, CK20 positive
- B. CK7 negative, CK20 positive
- C. CK7 positive, CK20 negative
- D. CK7 negative, CK20 negative



## 122. All tissues are correctly matched to their stem cell location, except:

- A. Intestine – Paneth cells near base of crypt
- B. Skin – Bulge region of hair follicle
- C. Liver – Canal of Hering
- D. Cornea – ~~Ciliary body~~ *Limbus*

140. Which of the following is called leukocyte common antigen?

A. CD10 - *CALLA*

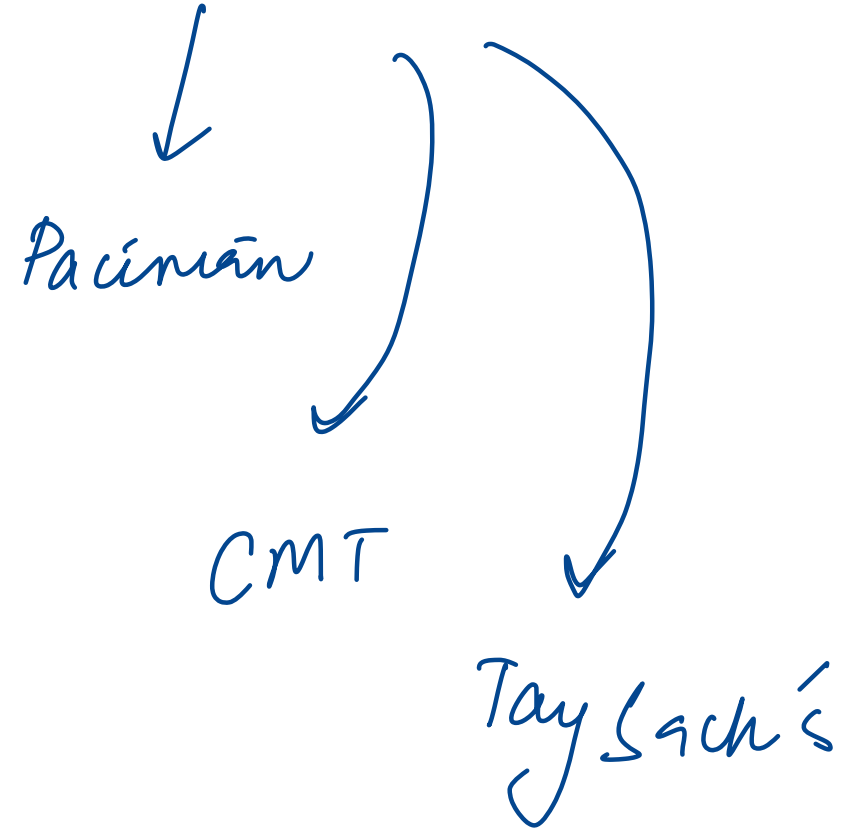
~~B. CD45~~

C. CD3

D. CD19

# 110. All of the following conditions show onion skin appearance, except:

- A. PSC *fibrosis*
- B. Systemic lupus erythematosus *vasculitis*
- C. ~~Marfan syndrome~~
- D. Ewing sarcoma



## 123. Which of the following is false regarding necrosis?

A. It is due to denaturation of protein ✓

B. It is due to enzymatic digestion ✓

C. It is an active process

D. Always pathological ✓

*passive*

*apoptosis*

## 132. All of the following are correct about amyloid appearance, except:

- A. Congo red under polarizing light – Apple-green birefringence (T)
- B. H&E stain – Basophilic extracellular substance eosinophilic
- C. Electron microscopy – Nonbranching fibrils
- D. X-ray diffraction –  $\beta$ -pleated sheet conformation

## 24. Which of the following statements about immunoglobulins is false?

~~A.~~ IgG is used to diagnose fetal infection **F**

B. IgM has weak precipitation activity **T**

C. IgG has four subclasses **T**

D. IgM is mainly intravascular **T**

**6. Which of the following best describes the structural characteristic that differentiates IgG from IgE?**

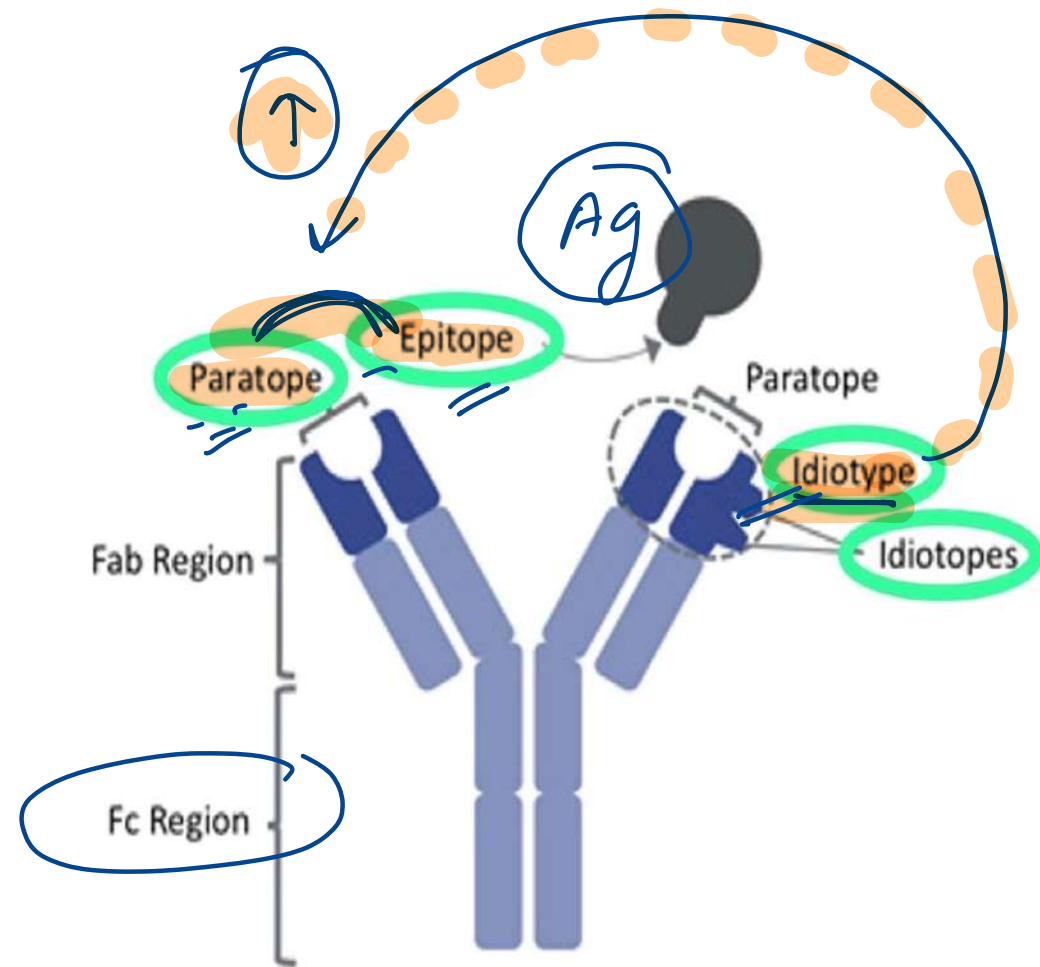
A. Idiotype

B. Isotype

C. Allotype

D. Epitope

- The isotype refers to the differences in the constant region of the heavy chains, which classify immunoglobulins into distinct types (e.g., IgG, IgA, IgE).
- Allotypes involve subtle genetic differences in constant regions but do not define immunoglobulin classes.
- The epitope refers to the specific part of the antigen recognized by the antibody.
- The region on an antibody (or B cell receptor) that specifically binds to an epitope.
- The idiotype defines antigen specificity.



isotype  
IgM / IgD


switching  
→

IgG / E / A

# GAMDE

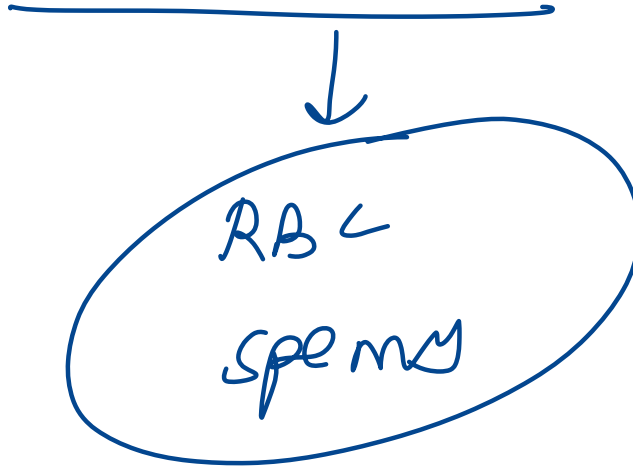
Ig Type	Half-life	Key Features
IgG	23 days	- Appears late → <b>chronic infection</b> - <b>Only Ig to cross placenta</b> - 4 subclasses - Opsonization, complement fixation, neutralization
IgA	6 days	- Two types: <b>Serum IgA &amp; Secretory IgA (dimer)</b> - Secretory IgA → <b>mucosal immunity</b>
IgM	5 days	- <b>Pentamer</b> , highest molecular weight - <u>Appears early</u> → <b>recent infection</b> - <b>Intravascular only</b> - Agglutination, hemolysis, opsonization
IgD	2-8 days	- <b>Surface Ig on B cells</b> - Acts as <u>antigen recognition receptor</u>
IgE	1-5 days	- <u>Type I hypersensitivity</u> - <b>Heat-labile</b> - Increased in <u>helminthic infections</u>

IgG 2  
recurrent sinusitis



## 7. Identify the cells that lack MHC class 1 antigen:

- A. Platelets
- B. T lymphocytes
- C. NK cells
- D. Red blood cells

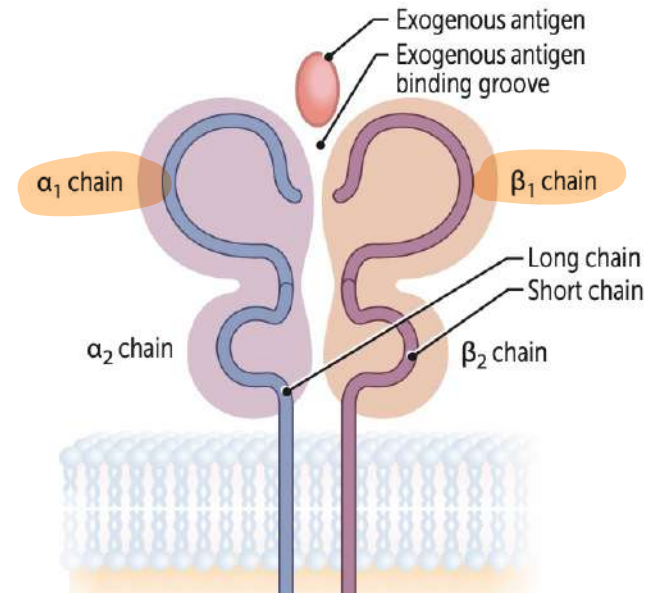
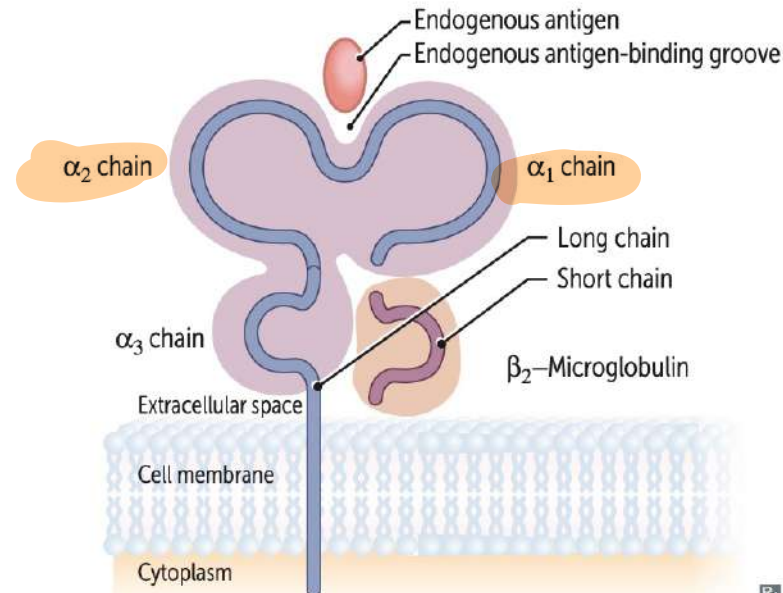


**Major histocompatibility complex I and II**

MHC encoded by HLA genes. Present antigen fragments to T cells and bind T-cell receptors (TCRs).

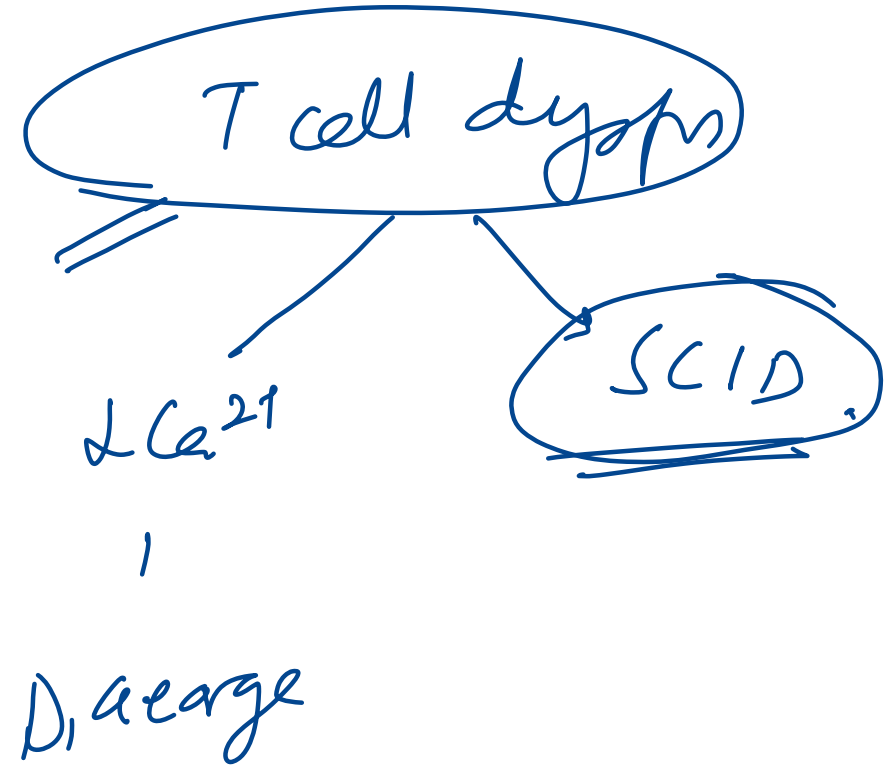
	<b>MHC I</b>	<b>MHC II</b>
LOCI	HLA-A, HLA-B, HLA-C MHC I loci have 1 letter	HLA-DP, HLA-DQ, HLA-DR MHC II loci have 2 letters
BINDING	TCR and CD8 (CD8 × MHC 1 = 8)	TCR and CD4 (CD4 × MHC 2 = 8)
STRUCTURE	1 long chain, 1 short chain	2 equal-length chains (2 α, 2 β)
EXPRESSION	All nucleated cells, APCs, platelets (except RBCs)	APCs
FUNCTION	Present endogenous antigens (eg, viral or cytosolic proteins) to CD8+ cytotoxic T cells	Present exogenous antigens (eg, bacterial proteins) to CD4+ helper T cells
ANTIGEN LOADING	Antigen peptides loaded onto MHC I in RER after delivery via TAP (transporter associated with antigen processing)	Antigen loaded following release of invariant chain in an acidified endosome
ASSOCIATED PROTEINS	β <sub>2</sub> -microglobulin	Invariant chain

**STRUCTURE**



8. A 4-month-old baby was brought with history of recurrent infections in the past 4 months. On examination white patches were present in oral mucosa which could be scraped easily. Which of the following statements is false about this condition?

- A. It has autosomal as well as X linked inheritance
- B. Adenosine deaminase enzyme is deficient
- C. ~~Tonsils are present~~ / Thymus
- D. B-cell count may be normal



**11. Which of the following mediators of inflammation is an example of a C-X-C chemokine?**

A. Lipoxin LXA-4

B. IL-8

C. Lymphotoctin

D. Fractalkine

## chemokines

Class	Structure	Example(s)	Key Features
<b>CXC</b>	2 cysteines separated by 1 amino acid (C-X-C)	<u>IL-8 (CXCL8)</u> , CXCL1	Neutrophil chemoattractants; act via CXCR receptors
<b>CC</b>	2 adjacent cysteines (C-C)	<u>MCP-1 (CCL2)</u> , <u>RANTES</u>	Recruit monocytes, eosinophils, basophils, T-cells
<b>C</b>	Only 1 cysteine (1st and 3rd missing)	<u>Lymphotactin (XCL1)</u>	Limited, found mainly in T-cells
<b>CX3C</b>	2 cysteines separated by 3 amino acids	<u>Fractalkine (CX3CL1)</u>	Membrane-bound and soluble forms; attracts T/NK cells

23. A woman who came with complaints of fever, myalgia, and rash at 12 weeks of gestation is found to have positive IgM titers for rubella. She is advised MTP. If the pregnancy is taken to full term, which of the following triad of complications would you expect to see in the child?

A. Chorioretinitis, hydrocephalus, intracranial calcifications TUXO

B. ~~Sensorineural hearing loss~~, ~~blueberry muffin rash~~, ~~microcephaly~~ CMV

C. Cataracts, cicatricial skin lesions, limb defects VZV

~~D. Sensorineural hearing loss, cataract, congenital heart defects~~

# 144. Which color vacutainer will you pick for PT and aPTT?

A. Lavender

B. Green

C. Red

D. Blue

- ESR Westergren

Wintrobe ESR

# GENERAL PHARMACOLOGY

---

**148. According to the Drugs and Cosmetics Act, prescription drugs fall under which schedule?**

A. Schedule P

B. Schedule D

C. Schedule H

D. Schedule Y

Schedule	Details
C	<b>Biological products</b>
D	Drugs <b>exempted from import provisions</b>
F	<b>Blood &amp; blood products</b>
FF	<b>Ophthalmic preparation standards</b>
G	<b>Under medical supervision</b>
H	<b>Prescription drugs</b>
J	Drugs that <b>cannot prevent/cure diseases</b>
M	<b>Good manufacturing practices</b>
P	<b>Life period &amp; storage</b> of drugs
W	<b>Generic name</b> marketed drugs
X	Drugs with <b>abuse and dependence liability</b> -Morphine / <i>Kelamine</i>
Y	<b>Import/manufacture/clinical trial</b> guidelines
Z	<b>Veterinary drugs</b>

160. Which of the following anti-obesity drugs is a selective 5-HT<sub>2C</sub> receptor agonist?

A. Orlistat *Lipase* (-)

B. Phentermine *Symp* (+)

C. Lorcaserin

D. Topiramate



**Anti-obesity Approved drugs:**

Phentermine + topiramate

Bupropion + zonisamide

Liraglutide, Semaglutide *GLP 1 (+)*

Tirzepatide: GIP + GLP-1 + QQ *→ Monnjaro*

Orlistat, Cetilistat: Lipase -

Locaserin-5HT2C +




Naltrexone

*ozempic.*

*→ Monnjaro*

153. All of the following are correctly matched drug-induced liver pathologies, except:

- A. Valproate – Microvesicular steatosis
- B. Halothane – Massive necrosis
- C. ~~Methotrexate~~ – Cholestatic pattern
- D. Allopurinol – Fibrin ring granulomas

Pathology/Pattern	Causative Agent
Cholestatic pattern 	Contraceptive and anabolic steroids 
Spotty hepatocyte necrosis	Methyldopa, phenytoin
Massive necrosis	Acetaminophen, halothane
Chronic hepatitis	Isoniazid
Microvesicular steatosis 	<u>Valproate</u> , <u>tetracycline</u> , <u>aspirin (Reye syndrome)</u> , <u>ART</u>
Fibrosis and cirrhosis	Alcohol, <u>methotrexate</u> , enalapril, vitamin A
Noncaseating epithelioid granulomas	Sulfonamides, amiodarone, isoniazid
Fibrin ring granulomas	Allopurinol

<b>Microvesicular Steatosis</b>	<b>Macrovesicular Steatosis</b>
- Acute fatty liver of pregnancy	<b>Centrilobular predominant (zone III)</b>
- Reye's syndrome	- Obesity, NASH (Nonalcoholic steatohepatitis)
- Alcoholic foamy degeneration	- Late alcoholic liver disease
- Drug/toxin-induced (valproic acid, salicylates, parenteral tetracycline, hypoglycin A)	
	<b>Periportal predominant (zone I)</b>
	- Total parenteral nutrition (TPN)
	- AIDS, chronic hepatitis C
	- Phosphorus poisoning, exogenous steroids

164. Among the following antimuscarinic drugs used in the treatment of overactive bladder, which one shows direct spasmolytic activity on smooth muscles?

A. A) Tolterodine

B. B) Darifenacin

C. C) Oxybutynin

D. D) Solifenacin

↓  
intestine

↓  
Mebeverine

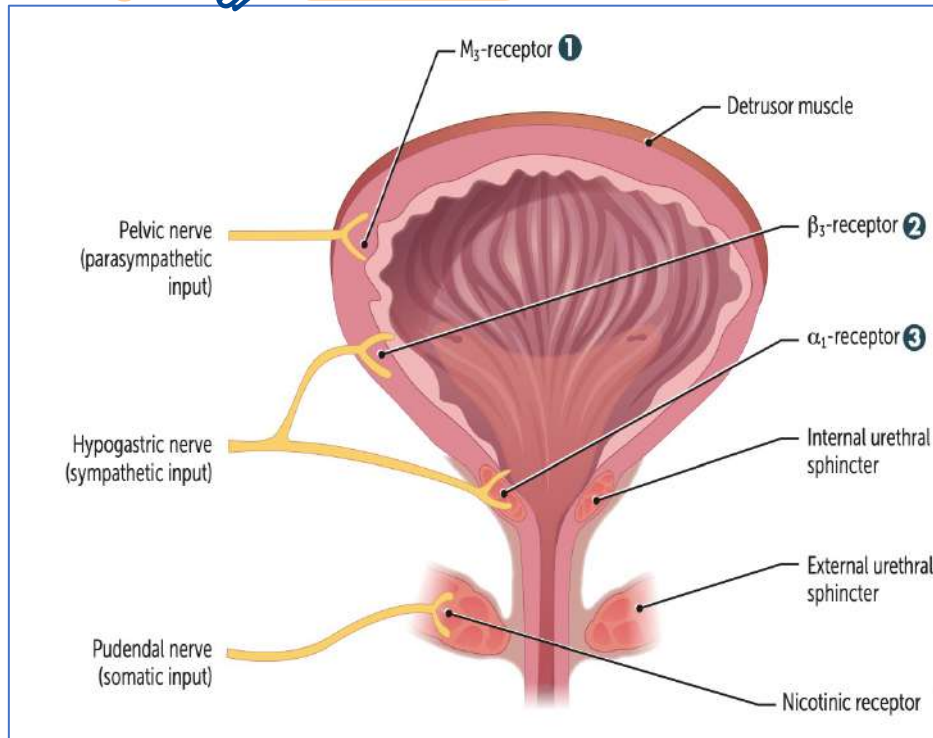
Agonist: BETHANECHOL

Antagonist: Solifenacin, Darfenacine (M3 selective)

Oxybutynin, Flvoxate (direct spasmolytic),

Tolterodine (bladder selective)

Trospium (only quaternary) → *x BBB — AD + incontinence*



MIRABEGRON

TAMSULOSIN

**182. A 48-year-old woman with CKD is scheduled for surgery. Her serum creatinine is 2.4 mg/dL and eGFR is 13. Which of the following opioids can be safely used in her?**

A. Pethidine

**B. Remifentanyl**

pseudoch

C. Alfentanil

D. Morphine

193. A 45 year old male with erectile dysfunction was prescribed sildenafil. He develops bluish-green vision. Inhibition of which enzyme is the cause?

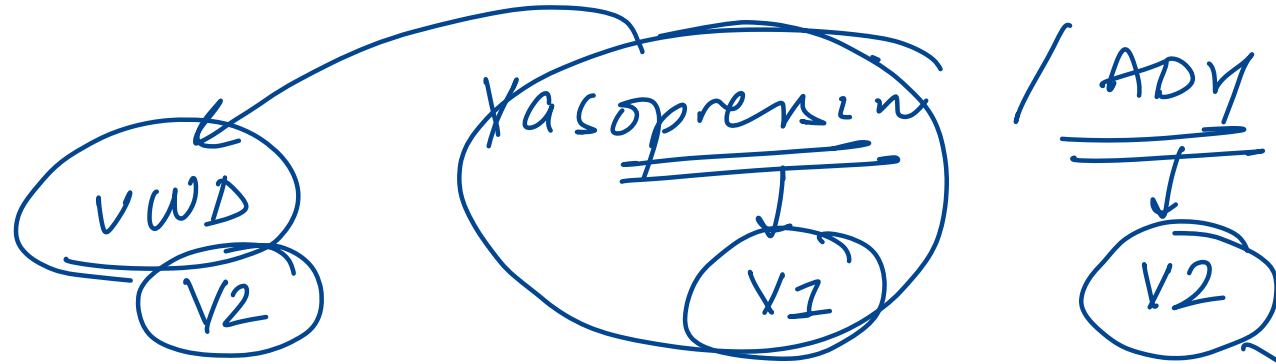
- A. Phosphodiesterase 3
- B. Phosphodiesterase 5
- C. Phosphodiesterase 6
- D. Phosphodiesterase 2

PDE 5 ⊖

178. A patient with central diabetes insipidus is prescribed intranasal desmopressin. Which of the following is not a valid reason for preferring it over intravenous vasopressin?

- A. Lower vasoconstrictor effect
- B. Prolonged duration of action
- C. Enhanced potency
- D. Greater selectivity for V1 receptor

× ×



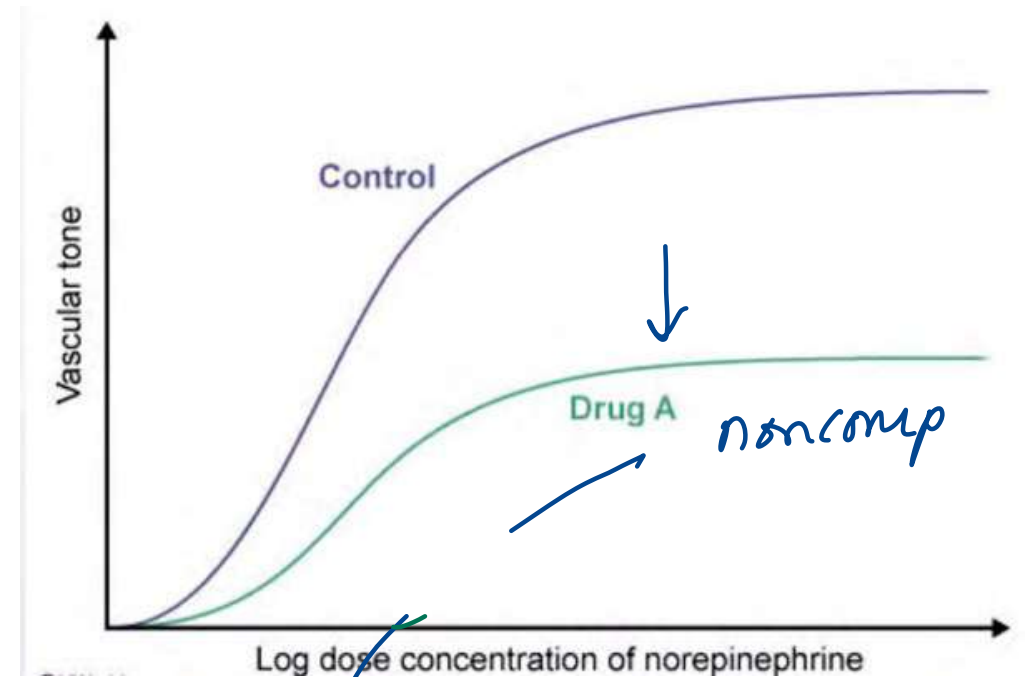
Receptor	Localization & Function
V <sub>1a</sub>	Mediates vasoconstriction, platelet aggregation, glycogenolysis(liver), and uterine contraction.
V <sub>3</sub> / V <sub>1b</sub>	Located in the anterior pituitary. Responsible for stimulating ACTH release.
V <sub>2</sub>	Promotes AQP2 upregulation, vWF and factor VIII release, and vasodilation.

vcd

50. An experiment tests vascular response to norepinephrine with and without Drug A. Graph below shows Drug A curve is shifted right and down. Drug A is most similar to which agent?

- A. Atropine
- B. Labetalol
- C. Phenoxybenzamine
- D. Phentolamine

*non comp / mixed*  
*Comp / rev.*



HELP  
 efficacy ← potency ← comp

**89. All of the following drugs show increased absorption with food, except:**

- A. Halofantrine
- B. Lithium
- C. Griseofulvin
- D. Azithromycin

↑ food

- Lithium
- Fibrates
- Halofantrine
- Lumifantrine
- Griseofulvin qq
- Bedaquiline

# 96. All of the following are true for non-microsomal enzymes, except:

A. Found in cytoplasm and mitochondria

(T)

B. Not inducible

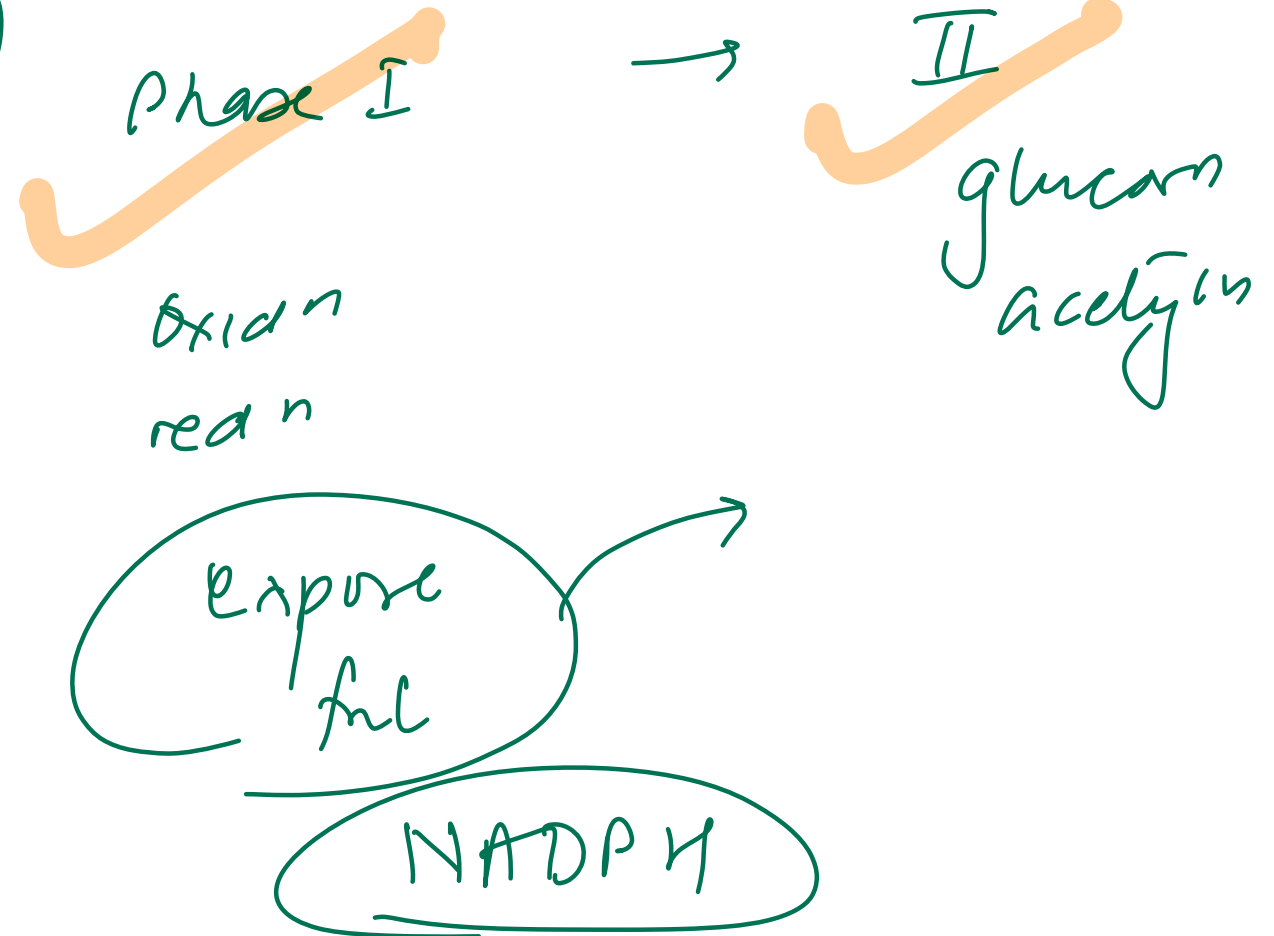
(T)

C. Carry out glucuronidation reactions

X

D. Include esterases and amidases

(T)



Feature	Non-Microsomal Enzymes	Microsomal Enzymes
Location	Cytoplasm and mitochondria of hepatic cells, also in other tissues including plasma	Smooth endoplasmic reticulum (primarily in liver; also kidney, intestinal mucosa, lungs)
Reactions Catalyzed	Some oxidations and reductions, many hydrolytic reactions, and <b>all conjugations except glucuronidation</b>	Most of the <b>oxidations, reductions, hydrolysis, and glucuronide conjugation</b>
Induction	<b>Not inducible</b>	<b>Inducible</b> by drugs, diet, and other agents
Examples	Esterases, amidases, some flavoprotein oxidases, most conjugases	Monooxygenases, <del>cytochrome</del> P450, UGTs, epoxide hydrolases, etc.

## 118. Which of the following statements about Trastuzumab is true?

- A. It is produced entirely from mouse
- B. It is a monoclonal antibody produced by injecting HER-2 antigen
- C. It is a polyclonal antibody
- D. It is a monoclonal antibody containing only human component

Type	% Human	Suffix	Example
Murine <i>o</i>	0%	-omab <i>o</i>	Tositum <u>o</u> mab
Chimeric <i>xi</i>	65%	-ximab <i>xi</i>	Ritu <u>x</u> imab
Humanized <i>zu</i>	95%	-zumab <i>zu</i>	Trastu <u>z</u> umab
Fully human <i>u</i>	100%	-umab <i>u</i>	Adalim <u>u</u> mab

*vi*  
*tox*

*xi*  
*-*

114. A 42-year-old male is brought to the ED after ingesting multiple acetaminophen tablets along with alcohol in a suspected suicide attempt. He has no chronic alcohol use history. The physician informs the family that acute ethanol ingestion may reduce acetaminophen toxicity. Which mechanism best explains this protective effect?

A. Ethanol competitively inhibits hepatic cytochrome P450

B. Ethanol depletes hepatic glutathione levels

C. Ethanol induces hepatic cytochrome P450

D. Ethanol impairs intestinal absorption of acetaminophen

PCM + alcohol

chronic ethanol

• **Acetaminophen**

- ~90% → Sulfation and Glucuronidation → **Nontoxic metabolites** (excreted in urine)
  - ~8% → **CYP450** → **NAPQI** X X
    - NAPQI + **Glutathione** → **Conjugated NAPQI** (excreted in urine)
    - If unconjugated → **Unconjugated NAPQI** → **Hepatotoxicity**
- **N-acetylcysteine**: increases **Glutathione** availability

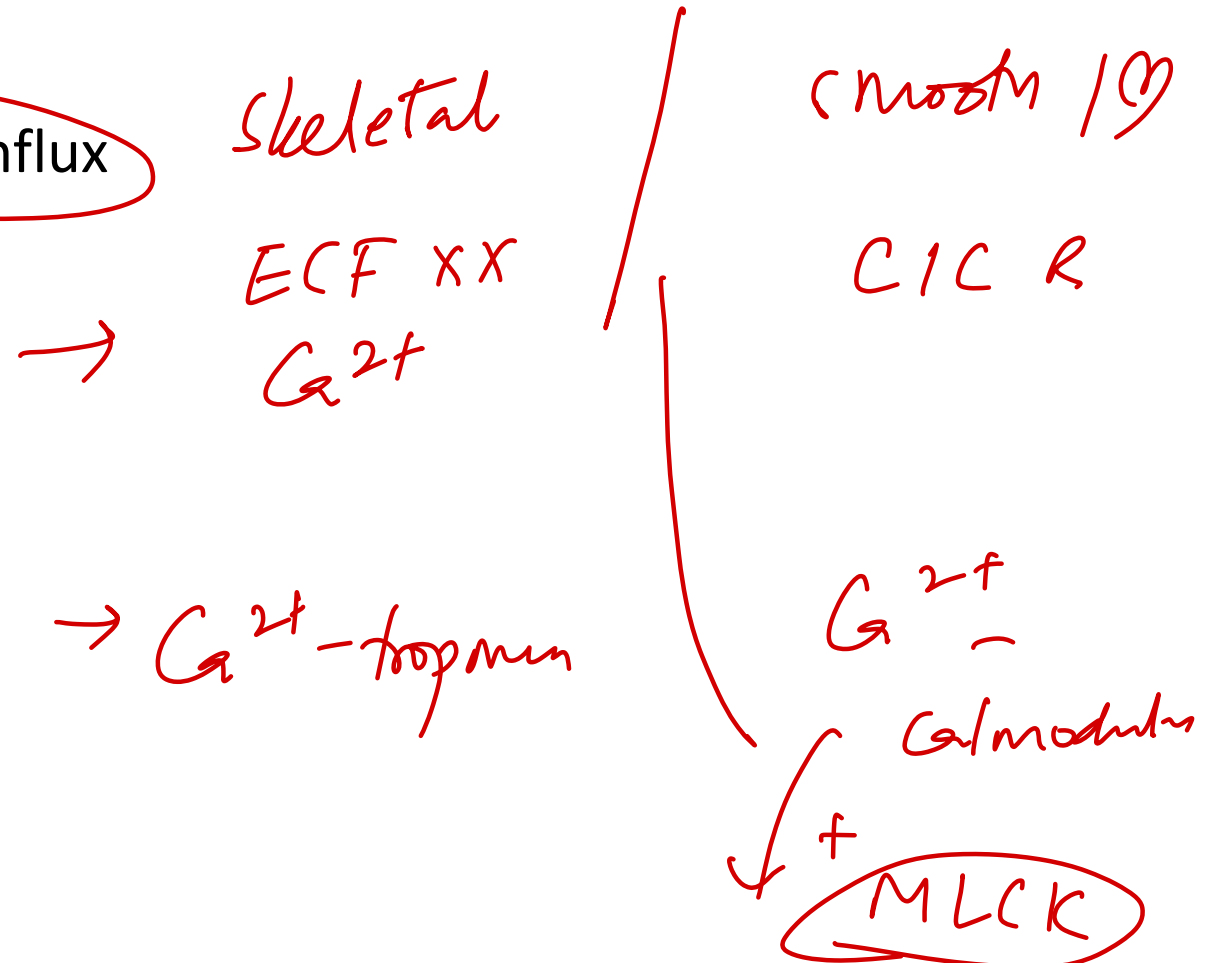
Alcohol

# General Physiology

---

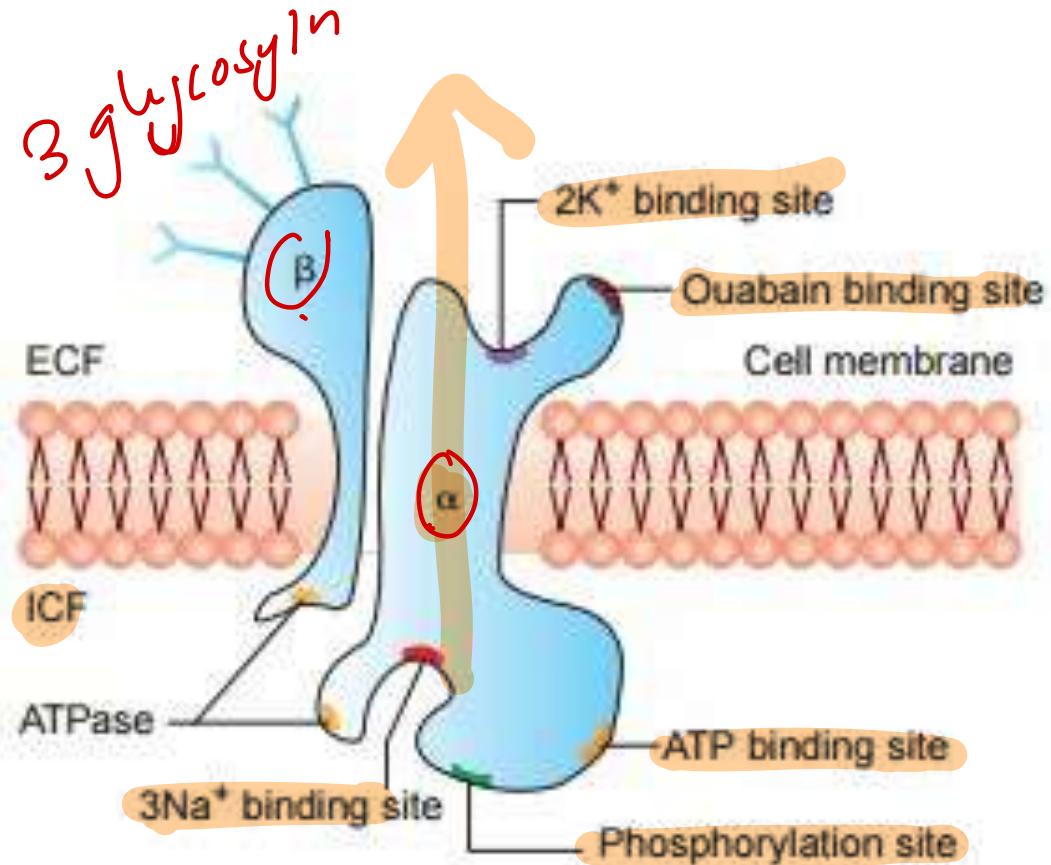
40. A 55-year-old man with hypertension is prescribed verapamil. Which skeletal muscle feature explains its resistance to this medication?

- A. Calmodulin-independent ~~excitation-contraction~~ coupling
- B. Decreased troponin affinity to calcium
- C. Elaborate T-tubular system
- D. Little dependence on extracellular calcium influx



4. All of the following are true regarding Na<sup>+</sup>/K<sup>+</sup> ATPase structure, except:

- A. ATP binding site is located intracellularly
- B. K<sup>+</sup> binding site is on the extracellular side
- C. Ouabain binds to the ~~cytoplasmic~~ domain
- D. Phosphorylation site is intracellular



NO ICIA  
3 Na<sup>+</sup> out      2 K<sup>+</sup> in

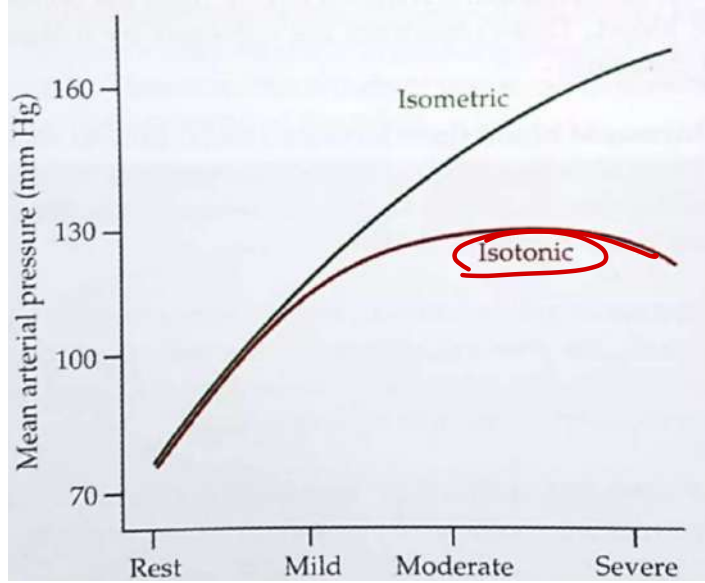
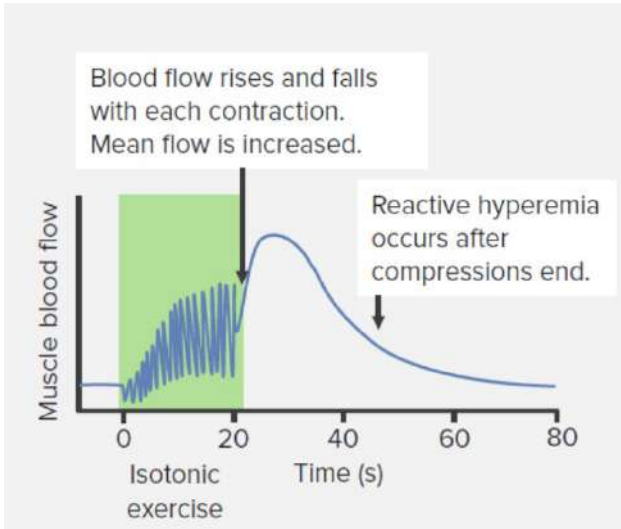
Coupling ratio: 3:2  
 Stimulated-Thyroid, insulin, Aldosterone



14. A 48-year-old man with diabetes undergoes stress testing. He walks for 7 minutes without chest pain. Peak heart rate is 132/min, BP increases from 95 to 112 mm Hg. Which of the following parameters was most likely decreased during peak stress?

*Isotonic*

- A. Cardiac output
- B. Left ventricular end-diastolic pressure
- C. Systemic systolic blood pressure
- D. Total systemic vascular resistance



**Isotonic exercise:**

- CO: ↑
- HR: ↑
- SV: ↑
- SBP: ↑
- TPR: ↓
- DBP: ↓
- MAP: ↓

**Isometric exercise:**

- CO: ↑
- HR: ↑
- SV: ≈
- SBP: ↑
- TPR: ↑
- DBP: ↑
- MAP: ↑

**18. All of the following increase the rate of diffusion across a membrane, except:**

A. Increased membrane thickness

B. Increased temperature

C. Greater lipid solubility

D. Higher surface area



## Fick's Law

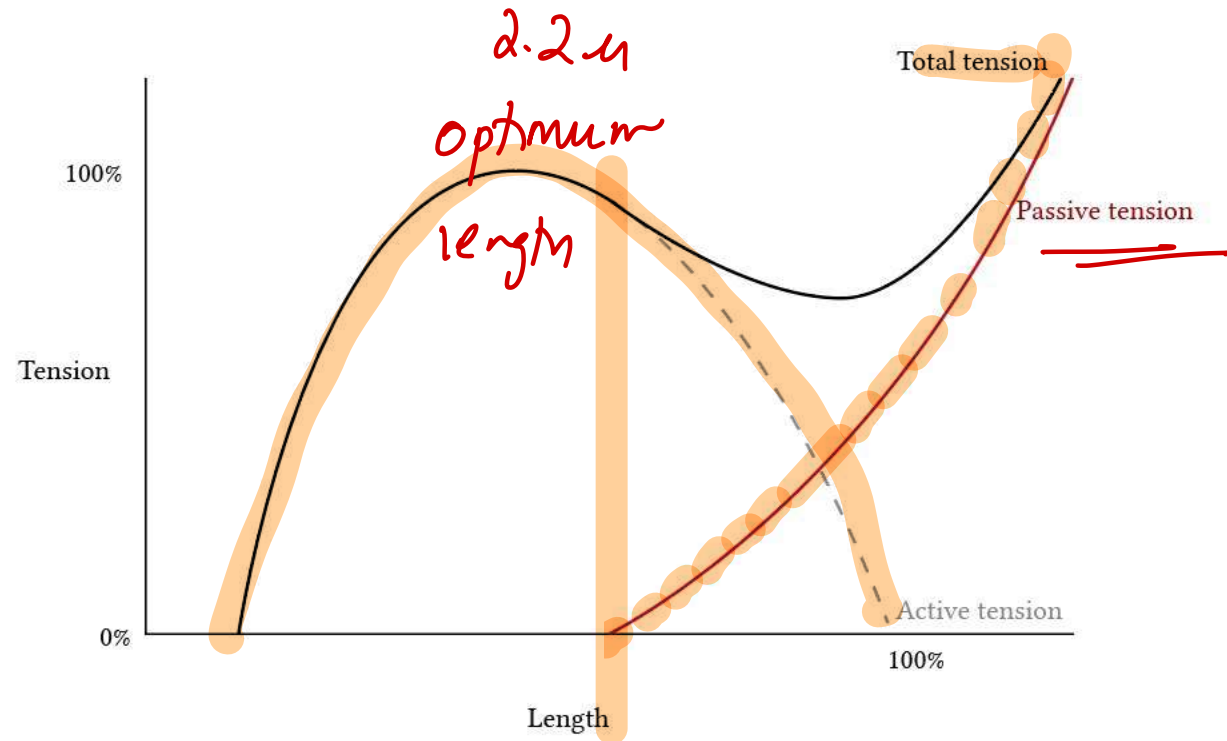
### ✓ Diffusion Equation

$$\dot{V}_{gas} = \frac{D * (P_1 - P_2) * A}{T}$$

- Diffusion Coefficient (D)
- Partial pressure gradient (P<sub>1</sub> - P<sub>2</sub>)
- Surface area (A)
- Thickness of barrier (T) *1/2*

### 38. All are correct statements about muscle tension curves, except:

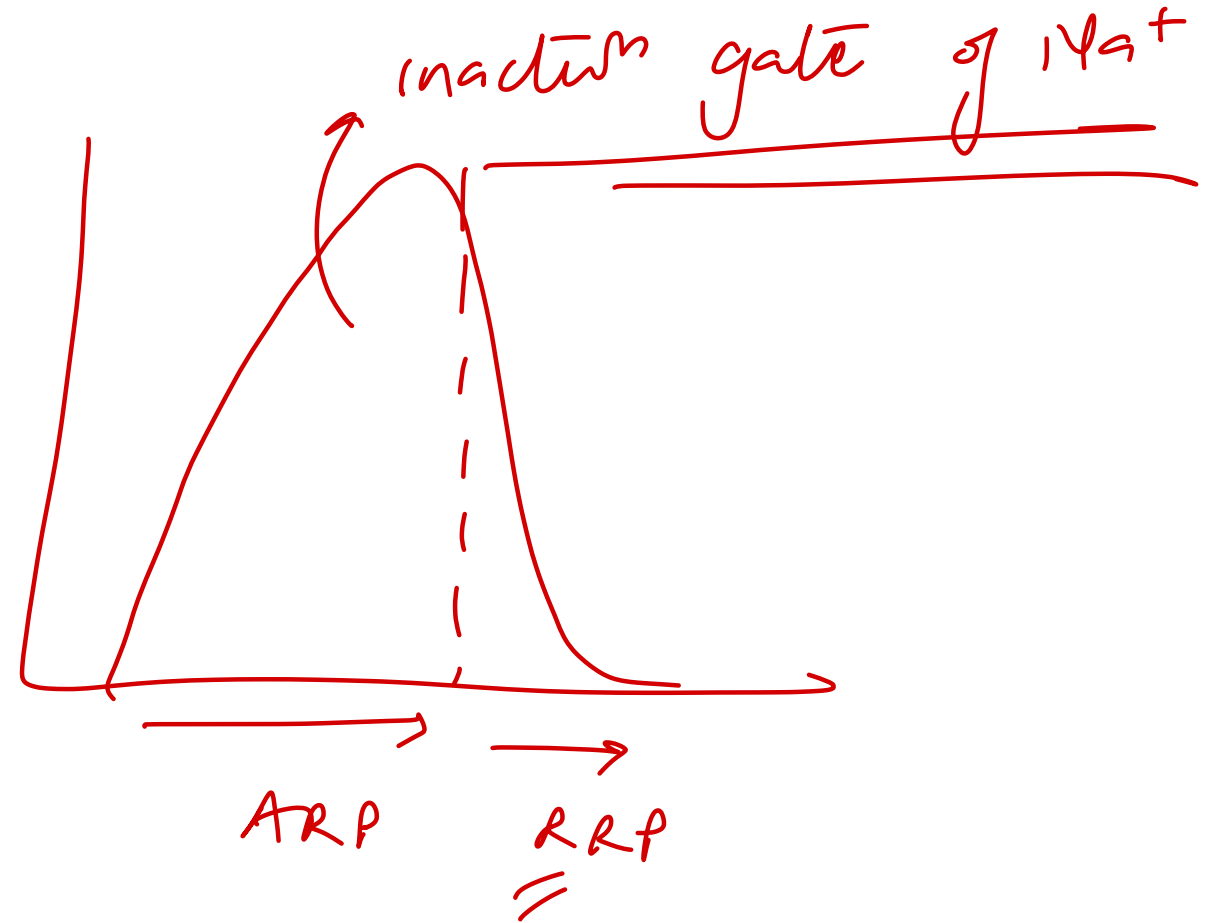
- A. Passive tension increases with muscle stretch  $\tau$
- B. Active tension is highest at optimal length  $\tau$
- C. Total tension equals sum of passive and active tension  $\tau$
- D. Passive tension is highest at resting muscle length ~~XX~~



Component	Source	Behavior
<b>Active tension</b>	Actin-myosin interaction	Maximal at optimal length (~100%)
<b>Passive tension</b>	Elastic connective tissues	Rises after the muscle is stretched
<b>Total tension</b>	Active + Passive	Composite of both

## 125. When does the relative refractory period begin?

- A. Quarter of repolarization
- B. Two-thirds of repolarization
- C. One-third of repolarization**
- D. Half of repolarization




161. Which of the following proteins connects the lines marked in the following image?

A. Actinin

B. Titin *longest*

C. Desmin

D. Myosin



Nebulin - stabiliser of actin  
Actin to 2  $\mu$ m  $\rightarrow$   $\alpha$ -actinin

Which of the following is a characteristic feature of single-unit (visceral) smooth muscle?

~~A) Absence of gap junctions~~ ✓

B) Each fiber functions independently ✓

C) Innervated by a single nerve ending per fiber ✓

D) Fibers are connected via many gap junctions and contract as a syncytium

Feature	Single Unit / Unitary / Visceral Smooth Muscle	Multi-Unit Smooth Muscle
Gap Junctions	Many gap junctions join the cell membranes; functions in a syncytial fashion	Each fiber is innervated by a single nerve ending ( <u>en passant endings</u> )
Response to Signals	Responds to hormones and other circulating substances	Mainly dependent on <u>nerve innervation</u>
Examples	Muscles of the <u>gut</u> , <u>bile ducts</u> , <u>ureters</u> , uterus, and <u>many blood vessels</u> (hollow viscera)	Ciliary muscle of the eye, iris, piloerector muscles, and arterioles ( <u>blood vessels have both types</u> )

# Which neuropeptide has an orexigenic effect?

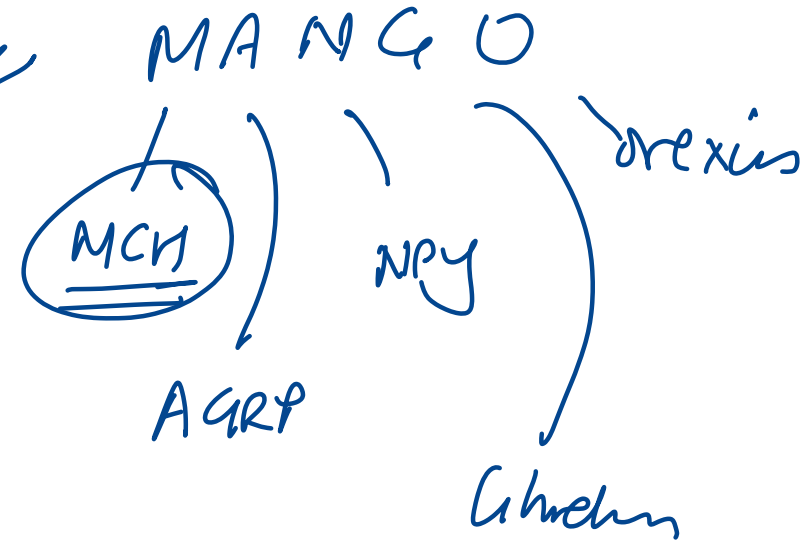
A) Melanocyte-stimulating hormone (MSH)

B) Leptin

C) Neuropeptide Y

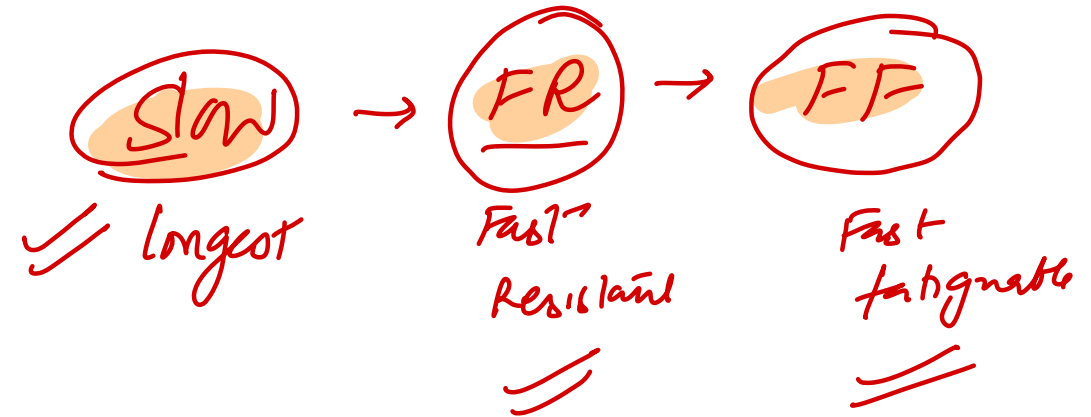D) Corticotropin-releasing hormone (CRH)

<u>Decrease Feeding (Anorexigenic)</u>	<u>Increase Feeding (Orexigenic)</u>
$\alpha$ -Melanocyte-stimulating hormone ( $\alpha$ -MSH)	Neuropeptide Y (NPY) ✓✓
Leptin	Agouti-related protein (AGRP) ✓✓
Serotonin	Melanin-concentrating hormone (MCH) ✓✓
Norepinephrine	Orexins A and B ✓
Corticotropin-releasing hormone	Endorphins
Insulin	Galanin (GAL)
Cholecystokinin (CCK)	Amino acids (glutamate and $\gamma$ -aminobutyric acid)
Glucagon-like peptide (GLP)	Cortisol
Cocaine- and amphetamine-regulated transcript (CART)	Ghrelin ✓✓
Peptide YY (PYY)	Endocannabinoids ✓✓



# Which of the following is correct about the recruitment of fast fatiguable motor unit?

- A) Recruited first
- B) Recruited last**
- C) During relaxation
- D) For the less demanding tasks



I slow Red ax

II

Feature	<u>Type I (Slow Oxidative)</u>	Type IIA ( <u>Fast Oxidative Glycolytic</u> )	Type IIB / IIX ( <u>Fast Glycolytic</u> )
Main source of ATP	Oxidative phosphorylation RED Mitochondria + Capillaries + Myoglobin +	Oxidative phosphorylation RED Mitochondria + Capillaries +	WHITE Glycolysis
Size of motor unit	Small	Large	Large
Resistance to fatigue	Fatigue resistant	Fatigue resistant	Fatigue susceptible

1st                                  2nd                                  3rd

What is this nail finding detected incidentally in a young girl called?

A) Beau's lines

B) Mees lines

C) Pterygium

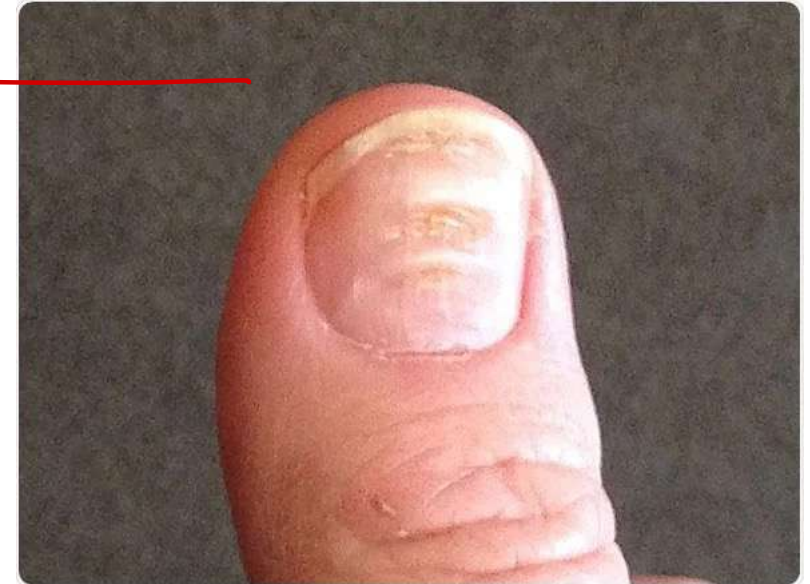d) Onychorrhexis

systemic / trauma

→ Az.

LP

→ systemic



Muehrke's - ↓ albumin

Terry - CHF / malnutrition